Genesis Journal of Surgery and Medicine

Genesis-GJSM-5(2)-49
Volume 5 | Issue 2
Open Access
ISSN: 3049-2254

Carcinoma Esophagus Presenting as a Second Malignant Neoplasm in a Completely Resolved Osteogenic Sarcoma - Rarest of Rare Occurrence

Dr Nimesh Shah, Dr Prashanth Rao and Dr Alpana Awasthi*
Gleneagles Hospitals, Mumbai

***Corresponding author:** Dr Alpana Awasthi, Gleneagles Hospitals Mumbai

Citation Shah N, Rao P, Awasthi A. Carcinoma Esophagus Presenting as a Second Malignant Neoplasm in a Completely Resolved Osteogenic Sarcoma - Rarest of Rare Occurrence. Genesis J Surg Med. 5(2):1-10.

Received: Novemebr 08, 2026 | **Published**: November 18, 2026

Copyright© 2026 Genesis Pub by Shah N, et al. This is an open-access article distributed under the terms of the Creative Commons Attribution 4.0 International License (CC BY 4.0). This license permits unrestricted use, distribution, and reproduction in any medium, provided the original author(s) and source are properly credited.

Abstract

We present you a unique and rare surgical case where in there was a second primary malignancy in a totally different organ system, as compared to a prior malignancy in different organ system, 42 years apart which the patient survived well regardless of any adversities.

Background

With increasing life expectancy and advances in diagnostic techniques, more individuals are living long enough to develop multiple cancers during their lifetime. Carcinoma Esophagus can be either squamous cell carcinoma or Adeno Carcinoma which are common entities in general population with rarity being extra – osseous osteosarcoma in Esophagus. Synchronous and Metachronous lesions are also common. However, it is extremely rare and as far as our knowledge is concerned this is the first case report presented in the world wherein a patient who developed an osteogenic sarcoma of tibia in his teens which was operated and received chemotherapy (No radiation) survived it and 40-42 years later developed adenocarcinoma of the esophagus and brilliantly survived that also. Minimally invasive surgeries, i.e. robot assisted Ivor Lewis esophagectomy not only reduces the length of incision but also reduces the post-operative length of stay, lessens the pulmonary and other infectious complications and helps the patient to return to their daily activities and to their work within no time.

Case report
The patient was diagnosed and operated for Osteogenic sarcoma of the proximal tibia of right lower limb at the age of 16 years, thereafter, was on regular follow -up. Patient was recently diagnosed with Carcinoma Esophagus after brief episodes of Dysphagia for which he was treated with Robotic Esophagectomy which led to the patient's early recovery with minimal complications.

Conclusion
Early diagnosis of any surgical condition, being it a carcinoma of any organ system can be cured with a multitude of therapies and inclusion of minimally invasive surgical techniques like Robotic Esophagectomy not only improve the quality of surgery but also shorten the recovery period post a supra-major surgery.

Keywords
Carcinoma Esophagus; Early Diagnosis; Robotic Esophagectomy.

Introduction

India ranks second globally in the number of esophageal cancer cases and deaths

Esophageal Cancer (EC) accounts as the 11th in the cancer incidence and the seventh position leading to cancer mortality in worldwide ranking [18].

It is a heterogeneous disease that can broadly be categorized into esophageal squamous cell carcinoma (ESCC) and esophageal adenocarcinoma (EAC) [5]. ESCCs closely resemble head and neck cancers, whereas EACs mimic gastric cancers [10]. Anatomically, the esophagus comprises three distinct sections of clinical relevance: cervical, thoracic, and abdominal. Even for non-metastatic disease, that undergoes potentially curative surgery, outcomes are poor, with five-year survival rates ranging from 20% to 35% [9].

For Locally advanced cancers, based on patient's performance status, neo-adjuvant chemoradiation followed by esophagectomy versus definitive chemoradiation is offered in case of ESCC.

For locally advanced EAC's neoadjuvant chemotherapy or chemoradiation is offered with surgery, or surgery alone in low-risk patients with well-differentiated tumors that are less than 2 cm in size [10]. Esophagectomy is associated with high morbidity and high mortality rates.

Secondary primary malignancy (SPM)is defined as a cancer which develops in a new tissue or organ after its initial diagnosis of the prior malignancy with a 6-month latency [3].

Metachronous as well as synchronous other primary cancers (OPC) in oesophageal cancer patients were more frequent in the recent period than in the previous period. We should consider antecedent, synchronous, and subsequent OPC in oesophageal cancer patients [4].

Although osteosarcomas of the oesophagus have been described in dogs, such tumours in humans do not appear to have been previously reported [2].

Extra skeletal Osteosarcoma (ESOS), a rare mesenchymal malignancy, manifests as an osteosarcoma within extraosseous organs and soft tissues. In contrast to primary osteosarcoma, which originates in the

bones and predominantly affects adolescents, ESOS is more commonly identified in adults over 50 years of age, with a marked male predominance [1].

Osteogenic sarcoma is a cancer of the teens which if localized can be tackled with surgery and chemotherapy alone but rarely may have to lead to amputation of the respective limb. Metastasis to lung have been noted [14].

We deal with a case here who was diagnosed with osteogenic sarcoma of the tibial bone at 15 years of age, underwent surgery for the same followed by chemotherapy at 16 years of age, full remission with no recurrence and 40 years later presented with second neoplasm i.e. Adenocarcinoma Esophagus. which was operated robotically wherein robot assisted esophagectomy done, with minimal complications, and pt recovered well and presently having normal food enterally with no dysphagia.

Case Presentation

57-year-old male first noticed difficulty in swallowing food, while eating at social gatherings. Gradually the symptoms progressed in a span of 2 weeks when the patient began to experience significant dysphagia to both hard and soft foods. Associated symptoms included nausea and regurgitation, but no emesis. The patient also reported fatigue, weakness while performing daily activities at work or home and an 8 – 10 kg weight loss over the period of 6 – 8 weeks (since March 2026). The patient was a life time non-smoker, occasionally used to take hookah, and frequently used to consume alcohol over weekends. Patient had a history of Osteogenic Sarcoma of Proximal Tibia (1984). Underwent surgery and chemotherapy for the same. The family history was negative for any malignancy and/or any familial syndromes associated with any cancer anywhere in the human system.

The patient was advised by his Gastroenterologist to undergo Upper Gastroscopy to reach to a diagnosis. This was also accompanied with Ct scan Abdomen and pelvis (plain plus iv plus oral contrast). Ct scan was suggestive of focal short segment circumferential thickening of distal esophagus with cholelithiasis and Sliding Hiatus hernia.

Upper GI scopy was suggestive of Diffuse Esophagitis with Hiatus Hernia (Hill's grade iv) and Barett's Esophagitis in lower esophagus, edema and neoplastic lesion? Stricture (**Figure 1**).



Figure 1: Upper gi scopy showing Impression: K/c/o ca esophagus - vertical extent of Barrett's mucosa till 32cm from upper incisors, distal narrowing. No other lesion seen.

On Histopathological examination there was poorly differentiated Adenocarcinoma with signet ring cells (her -2 Negative) PET -CT suggestive of Distal esophagus thickening at the level of D5 vertebra ,4.1 cm in length and maximum thickness 1.1 cm. Chemo port insertion (Left IJV) done and Chemotherapy started (details shared below) and 6 cycles completed. Also 2 cycles of Immunotherapy given. Post Chemotherapy PET – CT was suggestive of circumferential wall thickening noted involving lower thoracic esophagus, mucosal enhancement with diffuse linear low grade FDG uptake noted not seen involving Gastroesophageal junction, maximum thickness 1.2 cm with 4.5 cm length (**Figure 2**).

Left supraclavicular lymph node present with intermediate significance. Patient was taken up for surgery as there was no response to chemotherapy and Immunotherapy and also it was a surgically resectable tumor.

In summary patient is a case of CA ESOPHAGUS Post Neo – Adjuvant Chemotherapy (NACT), 2 cycles of FOLFOX (FOL**:** Folinic acid (also known as leucovorin+**F:** Fluorouracil (5-FU)+) **OX:** Oxaliplatin + 2 cycles of FLOT (Fluorouracil ie 5 -FU + Leucovorin + Oxaliplatin + Docetaxel) + NIVOLUMAB T3 NO Post FLOT (C2 – D15) + NIVOLUMAB (7th dose).

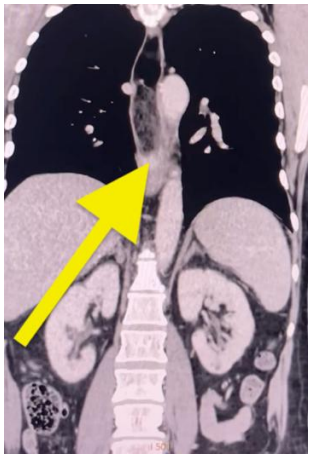

Figure 2: Coronal Ct scan showing the location of carcinoma esophagus and distal narrowing.

Surgery: Robot assisted Ivor Lewis Esophagectomy with robotic cholecystectomy with esophagogastric anastomosis with feeding jejunostomy with right Intercostal drain insertion. (**Figure 3 & 4**). (left femoral central line insertion done in view of lack of any peripheral lines and already presence of right PICC line and left chemo port insertion).

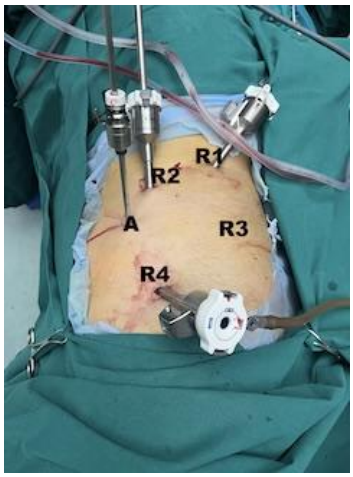

Figure 3: The port position in the thoracic part of Ivor Lewis Esophagectomy (robotic).



Figure 4: The post -operative surgical specimen with location of carcinoma.

Post-operative recovery: patient was shifted to surgical ICU for observation and further management.

- **Post operative (PO) D1:** ongoing ventilatory support.
- **PO D2:** Extubation done but the patient was started on High flow nasal Oxygen (HFNC). Patient was started on Subcutaneous enoxaparin 0.4 once a day. Jejunostomy feeds were gradually started.
- **PO D 3:** in view of saturation not maintaining well even with HFNC and chest Xray showing Left pneumothorax, pt was inserted left intercostal drain in the upper zone
- **PO D4 and D5:** patients' saturation gradually improved and he was mobilized out of bed.

Jejunostomy feeds were gradually increased to full feeds.

- **PO D6:** patient was shifted out of the ICU to the wards.
- **PO D7,8,9:** patient had one episode of fever 99-degree Fahrenheit, which was managed conservatively. Patient mobilizing well with walker and doing incentive spirometry. Left ICD was removed. And port site skin staples were removed. Right abdominal drain was removed.
- **PO D10:** To check for any anastomotic leak patient was taken for Fluoroscopy and CT scan screening. Evidence of a minor leak present.
- **PO D11:** left sided insertion of pigtail done with drainage of the collection.
- **PO D12 ,13:** sudden swelling of the left foot with gradual increase of the swelling to left calf and left thigh Venous Doppler done suggestive of subacute superficial and deep venous thrombosis. Dose of enoxaparin was increased to 0.6 twice a day.
- **PO D 14:** patient was discharged for home with Jejunostomy full feeds, left pigtail drain, right PICC line, Left chemo port,
- **PO D 15 – 20:** patient had on and off persistent loose stools and weakness on going
- **PO D 21:** In view of small anastomotic site leak with malnutrition, It was collectively decided to put a cover Syl metal stent to cover leak and encourage oral intake (**Figure 5**).

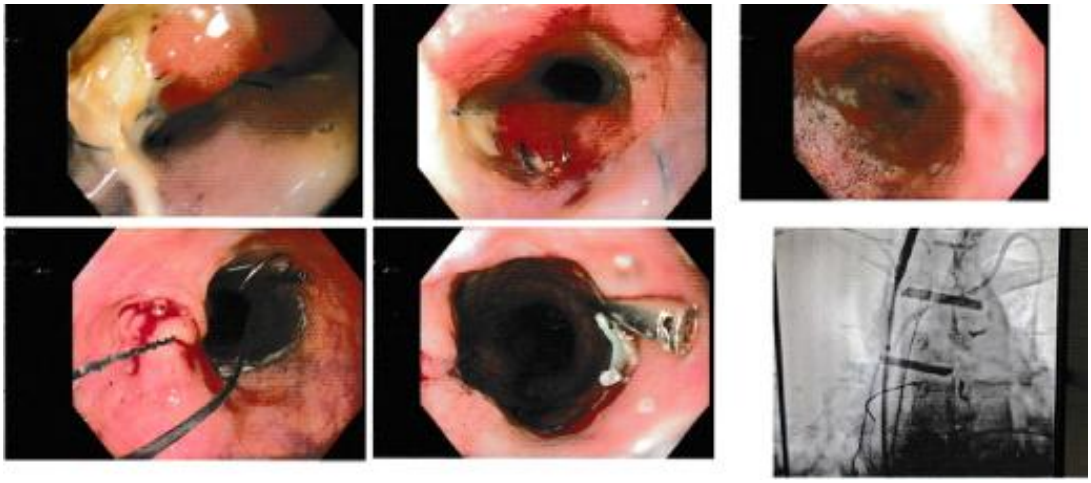

Figure 5: Esophagus: At 3O cm from the upper incisors anastomotic margin with leak seen. External markers placed at the L site Defect closed using Fully covered esophageal SEMS {10 cm X 18mm - BOSTON). Stent anchored at the site using KLOSURE hemoclip and endoscopic hand suturing using Covidien barbed suture.

- **PO D 22 – 28:** Oral feeds were gradually increased, and jejunostomy feeds were gradually reduced.
- **Po D 29 – 30:** Check x-ray done to see for position of the stent which was stable.

Post one and half month of surgery: left pigtail was out, patient tolerating full oral feeds and left lower limb swelling completely resolved.

Post metal stent removal patient is planned for further Immunotherapy twice weekly. Inj Nivolumab 240 mg.

Final Histopathology report:

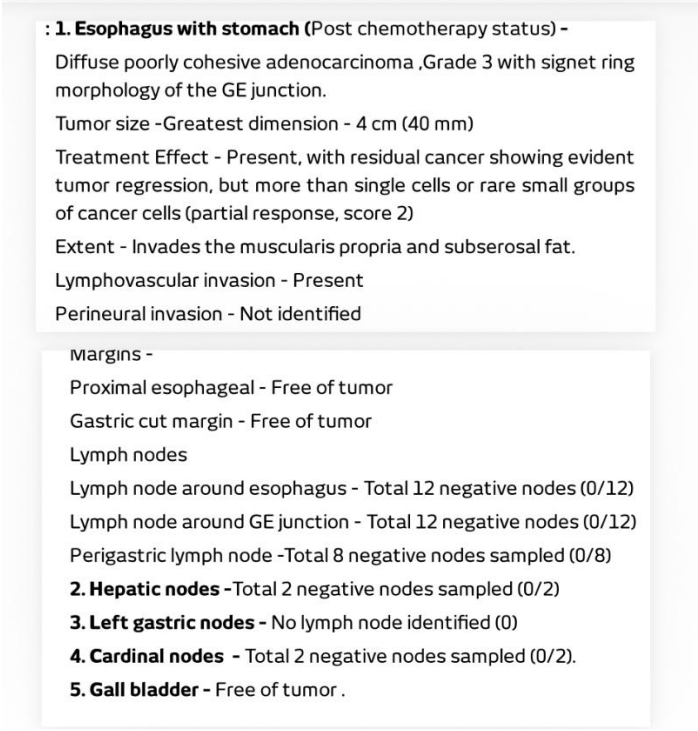

: **1. Esophagus with stomach (**Post chemotherapy status) **-**

Diffuse poorly cohesive adenocarcinoma ,Grade 3 with signet ring morphology of the GE junction.

Tumor size -Greatest dimension - 4 cm (40 mm)

Treatment Effect - Present, with residual cancer showing evident tumor regression, but more than single cells or rare small groups of cancer cells (partial response, score 2)

Extent - Invades the muscularis propria and subserosal fat.

Lymphovascular invasion - Present

Perineural invasion - Not identified

Margins -

Proximal esophageal - Free of tumor

Gastric cut margin - Free of tumor

Lymph nodes

Lymph node around esophagus - Total 12 negative nodes (0/12)

Lymph node around GE junction - Total 12 negative nodes (0/12)

Perigastric lymph node -Total 8 negative nodes sampled (0/8)

2. Hepatic nodes -Total 2 negative nodes sampled (0/2)

3. Left gastric nodes - No lymph node identified (0)

4. Cardinal nodes - Total 2 negative nodes sampled (0/2).

5. Gall bladder - Free of tumor .

Discussion

Esophageal Cancer (EC) remains to be the most important cause of death in EC patients with a prior cancer. EC related treatment should be actively adopted in patients with a prior cancer, as they were more likely to die from EC than the prior cancer.

EC patients with a prior Cancer had comparable overall survival than those without [8]. Only a few published studies have discussed the risk of developing a Second Primary malignancy SPM in primary cancer survivors. Saad et al investigated the impact of the prior cancer on survival outcomes of Stage IV EC patients, they found that prior cancers did not adversely impact survival of EC patients with Stage IV disease [11].

Besides, Chen et al explored Clinicopathological characteristics and prognosis of patients with EC as an SPM, and they demonstrated that lower M stage, the administration of surgery, and chemotherapy were tightly related to better overall survival (OS) for patients with EC as an SPM [12]. Dequing Pan et al in their study showed that the proportion of surgery was comparable in patients who died from EC with that in patients who died from prior cancer. Their findings strongly indicated that surgery was still an optional alternative for EC patients with a prior cancer.

In EC patients with a prior cancer, EC is most important cause of death regardless of clinical characteristics of the prior cancer and EC, Surgery for these patients decreased the risk of Esophageal Cancer, Second malignancy. These findings suggested that EC related treatment should be actively adopted in patients with prior cancers, as they are more likely to die from EC than prior cancer [8].

Solid tumors, as a whole, are more common sequelae of cancer treatment than hematologic malignancies. There are some cancers that are particularly prone to develop after certain types of primary cancer.

For Example,

- Breast cancer following Hodgkins Lymphoma
- Bladder cancer following Prostate Cancer
- Sarcoma following Breast Cancer.

Radiation therapy seems to confer higher risks for both solid and hematologic malignancies after many primary cancers, particularly in organs near and around original radiation field.

The combination of Radiation and Chemotherapy often increases the risk for solid tumors more than either mortality alone [13]. Osteosarcomas are uncommon malignant bone tumors which can develop with the formation of immature bone or osteoid. 3 % of total Childhood Cancers, peak is during growth spurt of adolescence. Risk factors being Prevalence of long bones near the metaphyseal growth plate caused by the exponential development of the bone during teenage growth spurt.

Radiation exposure is the ultimately recognized risk factor in the environment. As Osteosarcomas are not relatively sensitive to radiotherapy, only alternative is Resection, Chemotherapeutic Drugs such as cisplatin, doxorubicin and massive dose of methotrexate are most effective in osteosarcoma. Chemotherapy, specifically with alkalizing agents can give rise to secondary malignant neoplasms.

Ivor Lewis Esophagectomy, begins in the Abdomen and progresses through an assessment for metastatic disease, esophago-gastric mobilization with lymphadenectomy, conduit creation, pyloroplasty and feeding Jejunostomy insertion [15].

Approaches to Esophagectomy are open and minimally invasive. Minimally invasive Approaches include Laparoscopic and robot assisted. Robot-assisted minimally invasive Esophagectomy (RAMIE) has emerged as an alternative approach to standard laparoscopic and thoracoscopic minimally invasive esophagectomy.

The robot offers several advantages to standard minimally invasive techniques which include superior instrument dexterity, magnified stereoscopic and central optics, and direct control of multiple working instruments allowing self-assistance [16].

Advantages of RAMIE:

- Minimal mortality risk
- Decreased pulmonary related morbidity compared to open procedures
- Lower rate of pulmonary and infections complications in RAMIE compared to Open Esophagectomy
- No significant difference in Anastomotic leaks rates was noted, and overall perioperative mortality and length of stay were similar.
- Lower surgical complications

- Pulmonary and cardiac complications less frequent in RAMIE arm.
- Improved functional recovery at 14 days less mean overall postoperative pain scores, and improved quality of life measures in RAMIE.
- Improved lymph node evaluation
- Ramie has demonstrated intraoperative benefits including less blood loss and more complete lymphadenectomy, despite its longer operative time [17].

Ramie showed faster convalescence with a shorter length of stay (LOS), decreased pain, decreased ICU (Intensive Care Unit), admissions, and fewer infectious and cardio-pulmonary complications.

Due to rapid Development of Robotic Technology, RAMIE is also regularly carried out in major centers. Due to the 3D high definition, surgical field of view, surgical instruments with 7 degrees of freedom of movement, tremor filtering and good ergonomic experience, robot makes surgical operation more stable and precise [15].

Conclusion

Early diagnosis of Carcinoma Esophagus if made at the right time with the early starting of the treatment, with advantage of minimally invasive technique Like RAMIE can not only prevent any major complications but also lead to better survival of the patient without any or minimal morbidity.

- Rare occurrences of 2 malignancies in one person 42 years apart:
- 2 different organ systems
- 2 different phases of time
- 2 separate age groups
- 2 different pathologies
- 2 different treatments
- 2 times Survival.

One solution at both TIMES – SURGERY.

Acknowledgements

- We thank dr Vashisth Maniar and his team for his medical oncology support
- We thank dr Karan Anandpara (interventional Radiologist) for his support for his invasive lines.
- We Thank the Anesthesia team for their support for the long duration of the surgery
- We thank the ICU intensivist, ICU nursing staff and ICU ward staff for their co-operation
- We thank the Gastro endoscopy team especially Dr Shankar Zawar and his technical staff for his contribution for the metal stent placement and other endoscopic procedures.

Funding: Nil.

References

1. Shuai Luo, Xiaoxue Tian, Ting Xu, Qing Ji, Yao Li, et al. (2025) Primary extra skeletal osteosarcoma of the oesophagus with PPM1D-BCAS3 fusion: a case report and literature review. Front Med (Lausanne). 12:1558831.
2. Margaret McIntyre, John N. Webb, GC Browning. (1982) Osteosarcoma of the oesophagus. Hum Pathol. 13(7):680-2.
3. Surabhi Gupta Aishna NA. (2024) Primary carcinoma Oesophagus with unusual synchronous second malignancies: a case series. Indian J Case Reports. 8(12):3673.
4. Naohiko Koide, Komatsu D, Hiraga R, Kitazawa M, Suzuki A, et al. (2010) Oesophageal cancer associated with other primary cancers--historical comparison of clinicopathologic features in 359 oesophageal cancer patients. Hepatogastroenterology. 57(99-100):513-8.
5. S Nagasawa, M Onda, K Sasajima, K Takubo, M Miyashita. (2000) Multiple primary malignant neoplasms in patients with oesophageal cancer**.** S Nagasawa et al. Dis Oesophagus. 13(3):226-30.
6. Syllaios A, Vailas M, Tolia M, Charalampakis N, Vlachos K, et al.(2022) Radiation-Induced Oesophageal Cancer: Investigating the Pathogenesis, Management, and Prognosis. 58(7):949.
7. Wegner RE, McGrath KM, Luketich JD, Friedland DM. (2010) Extraosseous osteosarcoma of the oesophagus: a case report Rodney E Wegner et al. Sarcoma. 2010:907127.
8. Pan D, Xu W, Gao X, Yiyang F, Wei S, et al. (2021) Survival outcomes in oesophageal cancer patients with a prior cancer. Medicine (Baltimore). 100(7):e24798.
9. Teja R, Bhaskar R, Yadlapalli DC, Kukunuri S, Mohan R. (2025) Real-World Data of Esophageal Malignancies Managed Under the Government Scheme from a Tertiary Cancer Center in South India. Cureus. 17(1):e77850.
10. Hassanabad AF, Chehade R, Breadner D, Raphael J. (2020) Esophageal Carcinoma: Towards Targeted therapies. Cell Oncol (Dordr). 43(2):195-209.
11. Saad AM, Al-Husseini MJ, Elgebaly A, Aboshady OA, Salahia S, et al. (2018) Impact of prior Malignancy on outcomes of Stage IV esophageal carcinoma: SEER based study. Expert Rev Gastroenterol Hepatol. 12(4):417-423.
12. Chen Z, Li M, Ma K, Hu Z, Wang S, et al. (2020) Clinicopathological features and prognosis of patients with esophageal cancer: a large population-based analysis using the SEER program (2000–2015). Transl Cancer Res. 9(2):1113-24.
13. VanderWalde AM, Hurria A. (2011) Second Malignancies Among Elderly Survivors of Cancer. Oncologist. 16(11):1572-81.
14. Patiye S, Raut A. (2021) Osteosarcoma of the Right Proximal Tibia: A case report. J Pharma Res Inte. 33(47B):210-214.
15. Ackerman JM, Luketich JD, Sarkaria IS. (2021) Robotic Ivor Lewis Esophagectomy. 5:14.
16. Witek TD, Brady JJ, Sarkaria IS. (2021) Technique of Robotic Esophagectomy. J Thorac Dis. 13(10):6195-6204.
17. Fang C, Zhang L, Liang H, Xin Y, Zheng W, et al. (2024) Surgical Technique of da Vinci Robotic – assisted minimally invasic esophagectomy (RAMIE) expert experiences. 7(1):12-20.
18. International Agency for research on Cancer (IARC). Globocan 2022: esophagus Fact sheet official WHO/IARC statistics.