Genesis Journal of Dental Reports

Genesis-GJDR-2(1)-15
Volume 2 | Issue 1
Open Access

PRP Derived Exosome Therapy Following Arthrocentesis in a Patient with Temporomandibular Joint Disc Displacement without Reduction: A Case Report

Hacer Fulya Ucem*
Uskudar University Faculty of Dentistry, Department of Oral and Maxillofacial Surgery, Istanbul, Turkiye

***Corresponding author:** Hacer Fulya Ucem, Uskudar University Faculty of Dentistry, Department of Oral and Maxillofacial Surgery, Istanbul, Turkiye

Citation: Ucem HF. PRP Derived Exosome Therapy Following Arthrocentesis in a Patient with Temporomandibular Joint Disc Displacement Without Reduction: A Case Report. Genesis J Dent Rep. 2(1):1-06.

Received: June 16, 2026 | **Published:** June 30, 2026

Copyright© 2026 Genesis Pub by Ucem HF. This is an open-access article distributed under the terms of the Creative Commons Attribution 4.0 International License (CC BY 4.0). This license permits unrestricted use, distribution, and reproduction in any medium, provided the original author(s) and source are properlycredited.

Introduction

Disc displacement without reduction (DDwoR) is one of the most common intracapsular temporomandibular joint (TMJ) disorders and is characterized by persistent anterior displacement of the articular disc during both closed and open mouth positions [1,2]. Patients frequently present with severe pain, limited mandibular movement, impaired mastication, and reduced quality of life. In advanced cases, DDwoR may result in marked functional disability, including difficulty in oral intake and daily jaw activities [1,3].

Conservative treatment is generally considered the first line approach for DDwoR. However, when symptoms persist despite noninvasive management, minimally invasive procedures such as arthrocentesis have been widely recommended. Arthrocentesis has been shown to reduce intra articular inflammation, improve mandibular mobility, and alleviate pain in patients with symptomatic DDwoR [1,3-5].

In recent years, regenerative medicine has emerged as a promising field in the management of temporomandibular disorders. Among biologically based therapies, platelet rich plasma (PRP) has received considerable attention because of its anti-inflammatory and reparative properties. More

recently, exosomes have been recognized as key mediators of many regenerative effects previously attributed to cellular therapies [6,7].

Exosomes are Nano sized extracellular vesicles that contain proteins, lipids, messenger RNAs, and microRNAs involved in intercellular communication and tissue homeostasis [7]. Experimental studies have demonstrated that exosomes may promote chondrocyte proliferation and migration, suppress apoptosis, regulate extracellular matrix metabolism, and modulate inflammatory pathways associated with temporomandibular joint degeneration [6,8]. Furthermore, exosome mediated regulation of cytokine expression and macrophage polarization has been proposed as a potential mechanism contributing to pain reduction and restoration of joint homeostasis [6].

Despite increasing interest in exosome based therapies, clinical evidence regarding the use of PRP derived exosomes in temporomandibular joint disorders remains limited. Most currently available studies are preclinical and focus primarily on osteoarthritis models [6,8,9]. Therefore, the present case report describes the short term clinical outcomes of arthrocentesis followed by intra articular PRP derived exosome administration in a patient with severe symptomatic disc displacement without reduction.

Case Presentation

A female patient presented to our private clinic with complaints of severe left preauricular pain, restricted mouth opening, inability to chew properly, and difficulty in oral intake. The patient reported progressive worsening of symptoms, resulting in significant impairment of mastication and daily activities.

Clinical examination revealed marked tenderness upon palpation of the left temporomandibular joint. Mandibular opening was associated with severe pain and deviation toward the left side. Translation of the left condyle was markedly restricted. Baseline pain intensity was assessed using a 10 point Visual Analog Scale (VAS), revealing scores of 10/10 both at rest and during function. Maximum mouth opening (MMO) was limited to 23 mm.

Magnetic resonance imaging demonstrated anterior disc displacement without reduction in the left temporomandibular joint (Figure 1B). The disc remained anterior to the condyle in both closed and open mouth positions, indicating the absence of disc recapture (Figure1B,1D). In contrast, the right temporomandibular joint demonstrated mild anterior disc displacement with reduction (Figure 1A,1C).

Additionally, the left mandibular condyle appeared smaller and morphologically altered compared with the contralateral side, suggesting chronic condylar remodeling (Figure 1E). These imaging findings correlated with the clinical findings of severe pain, restricted mandibular movement, and deviation toward the affected side during opening.

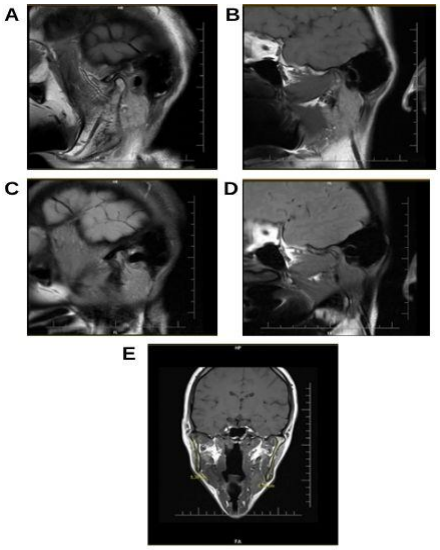

Figure 1: Magnetic resonance imaging findings of the temporomandibular joints.

(A) Closed mouth sagittal MRI of the left temporomandibular joint demonstrating anterior disc displacement. (B) Open mouth sagittal MRI of the left temporomandibular joint showing persistent anterior disc displacement without reduction. (C) Closed mouth sagittal MRI of the right temporomandibular joint demonstrating mild anterior disc displacement. (D) Open mouth sagittal MRI of the right temporomandibular joint demonstrating disc recapture, consistent with disc displacement with reduction. (E) Comparative sagittal MRI views showing reduced condylar morphology and remodeling of the left mandibular condyle compared with the contralateral side.

Considering the severity of symptoms and functional limitation, arthrocentesis of the left temporomandibular joint was performed under local anesthesia. Following the procedure, the patient was instructed to maintain a soft diet, avoid excessive mandibular movements, and minimize parafunctional habits. Subsequently, intra articular PRP derived exosome therapy was administered as an adjunctive biologic treatment (Figure 2A,2B).

The patient was followed weekly, and clinical outcomes were assessed using resting pain VAS, functional pain VAS, and maximum mouth opening measurements.

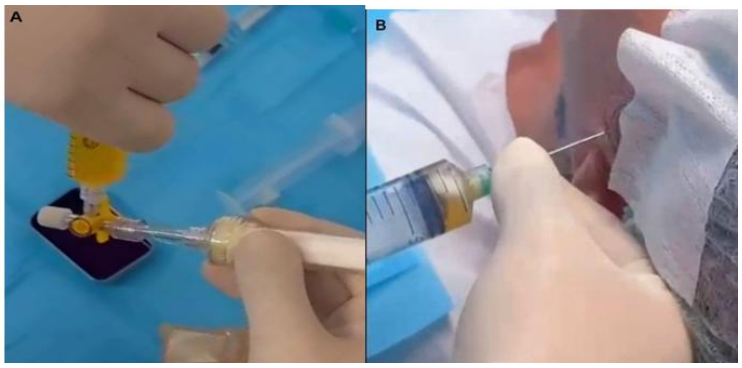

Figure 2: Preparation and intra-articular administration of PRP-derived exosome therapy.

Preparation of the PRP-derived exosome product prior to administration. (B) Intra-articular injection of PRP-derived exosome into the left temporomandibular joint under aseptic conditions.

Results

Pain intensity was evaluated separately at rest and during function using a 10-point Visual Analog Scale (VAS). Changes in pain scores and maximum mouth opening (MMO) during the follow-up period are summarized in (Table 1).

Time Point	Resting VAS	Functional VAS	MMO (mm)
Baseline	10	10	23
1 week after arthrocentesis	6	7	28
1 week after PRP derived exosome	6	6	31
2 weeks after PRP derived exosome	4	4	34
3 weeks after PRP derived exosome	4	4	34

Table 1: Clinical outcomes following arthrocentesis and PRP-derived exosome therapy.

One week after arthrocentesis, resting pain decreased from 10/10 to 6/10, while functional pain decreased from 10/10 to 7/10. Concurrently, maximum mouth opening increased from 23mm to 28mm.

Following PRP derived exosome administration, both resting and functional pain scores were recorded as VAS 6/10 during the first post treatment week, while MMO increased to 31mm. At the second week after exosome therapy, both resting and functional pain scores decreased to VAS 4/10, accompanied by an increase in MMO to 34mm. These improvements remained stable at the third week follow up.

Overall, maximum mouth opening increased by 11mm, corresponding to a 47.8% improvement compared with baseline measurements. Resting and functional pain scores decreased from 10/10 at baseline to 4/10 at the final follow up visit. The patient additionally reported substantial improvement in mastication, oral intake, and overall jaw function. No treatment related complications or adverse events were observed throughout the follow up period.

Discussion

The present case describes the short term clinical outcomes of arthrocentesis followed by intra articular PRP derived exosome administration in a patient with severe symptomatic disc displacement without reduction. At presentation, the patient exhibited severe pain, restricted mandibular movement, compromised nutritional intake, and significant functional disability.

Arthrocentesis is widely recognized as an effective minimally invasive treatment for symptomatic DDwoR. Previous studies have demonstrated improvements in pain and mandibular mobility following arthrocentesis, primarily through lavage of inflammatory mediators and release of intra articular adhesions [1,3-5]. Consistent with these findings, the present patient experienced an immediate improvement in both pain intensity and mouth opening after arthrocentesis.

Recently, exosome based therapies have emerged as a promising cell free regenerative approach for temporomandibular joint disorders. Exosomes contain a wide range of bioactive molecules, including

proteins, lipids, messenger RNAs, and microRNAs, which participate in intercellular signaling and tissue homeostasis [6,7]. Experimental studies have shown that exosomes may promote chondrocyte proliferation and migration, suppress apoptosis, regulate extracellular matrix metabolism, and modulate inflammatory pathways involved in joint degeneration [6,8].

In the present case, additional improvement in mandibular function was observed following PRP derived exosome administration, with MMO increasing from 28 mm after arthrocentesis to 34 mm during follow up. Furthermore, both resting and functional pain scores progressively decreased to 4/10 by the second week after exosome therapy. These findings may reflect the anti-inflammatory and biologically active properties attributed to exosomes.

However, the independent contribution of PRP derived exosomes cannot be definitively established because arthrocentesis was performed before exosome administration. The observed clinical improvement likely reflects the combined effects of arthrocentesis, biologic therapy, and supportive conservative measures.

Another limitation of this report is the short follow up period of three weeks. Although early clinical improvement was observed, conclusions regarding structural regeneration, disc recapture, cartilage repair, or long term disease modification cannot be drawn. Current evidence regarding exosome-based therapy in temporomandibular joint disorders remains largely limited to in vitro and animal studies, and well-designed prospective clinical investigations are still required [6,8,9].

Conclusion

Within the limitations of this case report, arthrocentesis followed by intra articular PRP derived exosome therapy was associated with short term improvement in pain intensity, mandibular function, maximum mouth opening, and oral intake in a patient with symptomatic disc displacement without reduction. Further prospective clinical studies with longer follow up periods are required to determine the therapeutic efficacy and long term outcomes of PRP derived exosome therapy in temporomandibular joint disorders.

References

1. Bhattacharjee B, Bera RN, Verma A, Soni R, Bhatnagar A. (2023) Efficacy of Arthrocentesis and Stabilization Splints in Treatment of Temporomandibular Joint Disc Displacement Disorder Without Reduction: A Systematic Review and Meta analysis. J Maxillofac Oral Surg. 22(1):8393.
2. de Almeida AM, Botelho J, Machado V, Mendes JJ, Manso C, González-López S. (2023) Comparison of the Efficacy of Two Protocol Treatments in Patients with Symptomatic Disc Displacement without Reduction: A Randomized Controlled Trial. J Clinl Med. 12(9):3228.
3. Grossmann E, Poluha RL, Iwaki LCV, Santana RG, Iwaki Filho L. (2019) The Use of Arthrocentesis in Patients with Temporomandibular Joint Disc Displacement Without Reduction. PLoS One. 14(2):e0212307.
4. Grossmann E, Poluha RL. (2022) Double-Puncture Versus Single-Puncture Arthrocentesis: A Randomized Controlled Trial with 3 Years of Follow-Up. J Oral Facial Pain Headache. 36(2):141-46.
5. Gupta A, Ali I, Zeeshan M, Singh S, Kumar A, Adil A. (2023) Role of Intra-articular Piroxicam in the Temporomandibular Joint After Arthrocentesis for Anterior Disc Displacement Without Reduction. Cureus. 15(2):e34580.

6. Yuan W, Wu Y, Huang M, Zhou X, Liu J, et al. (2022) A New Frontier in Temporomandibular Joint Osteoarthritis Treatment: Exosome-Based Therapeutic Strategy. Frontiers in Bioengineering and Biotechnology. Front Bioeng Biotechnol. 10: 1074536.
7. Liu Q, Wang R, Hou S, He F, Ma Y, et al. (2022) Chondrocyte-Derived Exosomes Promote Cartilage Calcification in Temporomandibular Joint Osteoarthritis. Arthritis Res Ther, 24(1): 44.
8. Kalluri R, LeBleu VS. (2020) The Biology, Function, and Biomedical Applications of Exosomes. Science, 367(6478) eaau6977.
9. Yuan W, Liu J, Zhang Z, Ye C, Zhou X, et al. (2025) Strontium-Alix Interaction Enhances Exosomal miRNA Selectively Loading in Synovial MSCs for Temporomandibular Joint Osteoarthritis Treatment. Int JOral Sci. 17(1): 6.