

Individualized Dental Implants for Severe Maxillary Atrophy: A Clinical Report with Two-Year Follow-Up

Iopes Joao Cracel, Fernandes Marta and Duarte Rui*

Clinica Santa Barbara

* **Corresponding author:** Duarte Rui, Clinica Santa Barbara

Citation: Rui D, Marta F, Cracel LJ Individualized Dental Implants for Severe Maxillary Atrophy: A Clinical Report with Two-Year Follow-Up. *Genesis J Surg Med.* 4(1):1-7.

Received: March 22, 2025 | **Published:** March 30, 2025.

Copyright © 2025 genesis pub by Rui D, et al. CC BY-NC-ND 4.0 DEED. This is an open-access article distributed under the terms of the Creative Commons Attribution-Non Commercial-No Derivatives 4.0 International License. This allows others distribute, remix, tweak, and build upon the work, even commercially, as long as they credit the authors for the original creation.

Abstract

Severe maxillary and mandibular atrophy presents significant challenges in prosthetic rehabilitation. This clinical report describes the treatment of a 66-year-old female patient with extensive maxillary and mandibular atrophy using individualized dental implants (Implantize Compact®, Boneeasy). The customized implants, designed based on reverse planning principles, were placed in the maxilla following Le Fort I fixation concepts and in the mandible following Champy's fixation principles. Immediate loading was performed with screw-retained prostheses. The patient was followed up for two years, demonstrating successful osseointegration, functional improvement, and no complications. This case highlights the efficacy of individualized implant solutions as a viable alternative for severe atrophic conditions.

Keywords

Severe Maxillary Atrophy, Individualized Dental Implants, Graftless Solutions for Dental Rehabilitation, Immediate Loading

Introduction

Severe maxillary atrophy is a condition that significantly compromises prosthetic rehabilitation, especially in edentulous patients. Conventional implant placement is often unfeasible due to limited bone volume, necessitating grafting procedures or alternative implant techniques. The advent of individualized dental implants has provided a graftless solution, offering improved stability and functionality. This report presents a case of successful rehabilitation using customized implants with immediate loading, demonstrating their potential as a first-line solution for extreme atrophic cases [1-4].

Clinical Case

A 66-year-old female patient presented with extensive atrophy of the maxilla and mandible, the patient is non smoker, no allergies referred, with hyperthyroidism and vitamin D deficiency.

Medical History: The patient reported having undergone full fixed rehabilitation with implants in 2014. They visited Clínica Santa Bárbara in 2022, presenting with peri-implantitis in all implants. In October 2022, all implants were removed, and acrylic removable full dentures were placed. In March 2023. The patient attends oral hygiene consultations every six months.

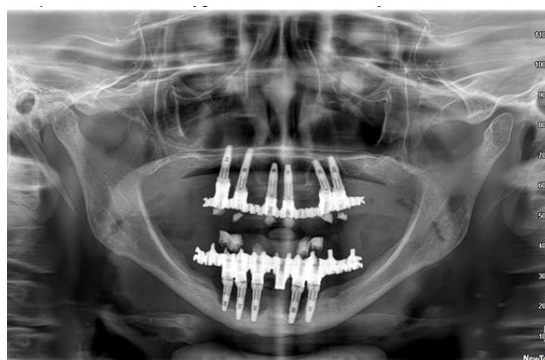

Figure 1: Initial stage.

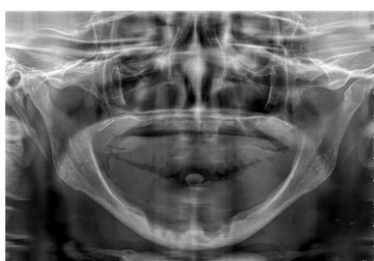

Figure 2: After implant explantation.

Treatment Plan

Given the severe atrophy, individualized implants (Implantize Compact®, Boneeasy) were chosen. These implants are based on Le Fort I fixation principles for the maxilla and Champy's fixation for the mandible, providing a stable foundation for screw-retained prostheses. The treatment workflow included [5-7]:

- **Reverse Planning:** A large field-of-view (FOV) CT scan was performed using a wax-up with radiopaque markers, enabling optimal implant positioning based on prosthetic needs.
- **Design and Manufacturing:** Segmentation was carried out using Realguide® software, and the implant was customized using Tailored Implant® software. The implant was 3D-printed, milled, polished, and treated with SLA surface modification to enhance osseointegration.
- **Sterilization:** The final implant was cleaned, packaged, and sterilized with ethylene oxide (ETO).

Surgical Procedure

Maxilla

- A horseshoe incision with distal relieving incisions was performed.
- A full-thickness flap was raised, exposing the malar bone, infraorbital foramen, and anterior nasal spine.
- A surgical guide was used to prepare sites for the dental connections.
- The implant was first secured with 2.0 mm screws before final fixation with 2.7 mm x 22 mm screws in the zygomatic bone.
- Tissue closure was achieved using mattress and single sutures.

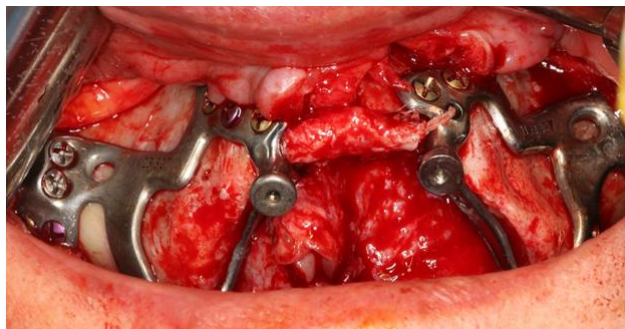


Figure 3: Implant placement on the maxilla.

Mandible

- A crestal incision with posterior relieving incisions was performed.
- A full-thickness flap was elevated, exposing the mental nerve, retromolar region, and mylohyoid muscle.
- Bone preparation was guided for dental connection placement.
- The implant was secured initially at the extremes, followed by fixation of all plate screws per technical specifications.
- Tissue closure was performed similarly to the maxilla.

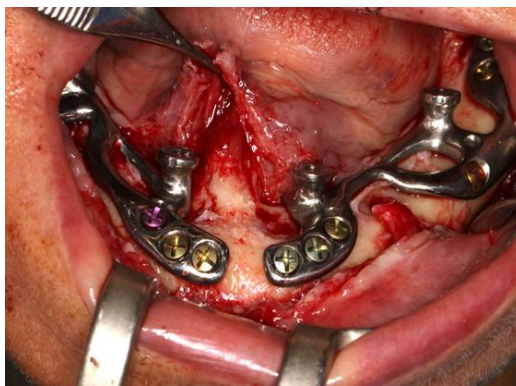


Figure 4: Implant placement on the mandible.

Prosthetic Rehabilitation

Immediate loading was achieved by capturing two acrylic prostheses during the same surgical session. Postoperative panoramic radiographs confirmed optimal adaptation.

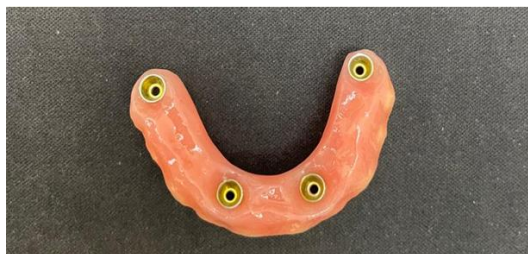

Figure 5: Provisional prosthesis for the maxilla.

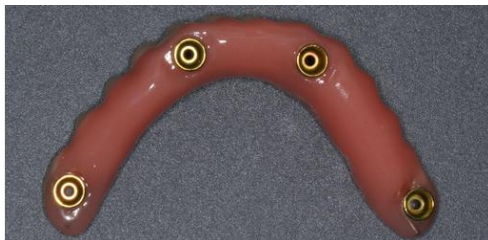

Figure 6: Provisional prosthesis for the lower jaw.

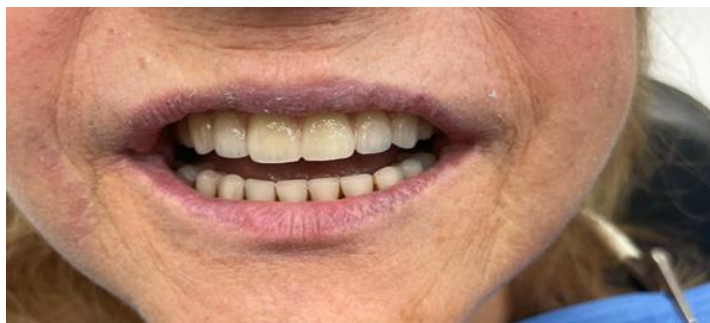

Figure 7: Immediate loading.

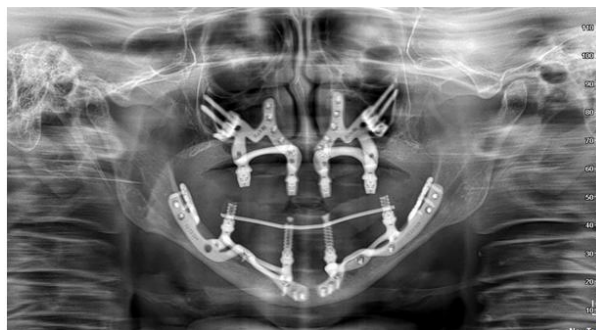


Figure 8: Pano x-ray immediate after surgery.

Results

The patient was followed up every six months for two years. No complications were observed. The patient reported improved confidence and functional rehabilitation, regaining the ability to chew without restriction, a capability lost for over 20 years. Radiographic evaluations confirmed stable implant integration with no signs of peri-implant bone loss.

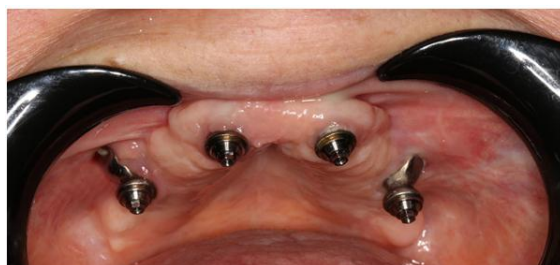

Figure 9: Upper follow up 2 years after.

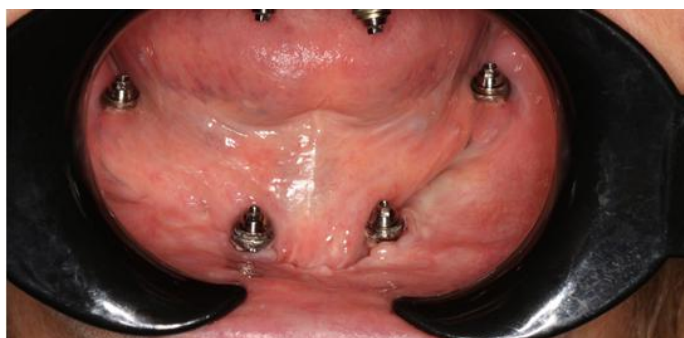

Figure 10: Lower jaw follow up 2 years after.

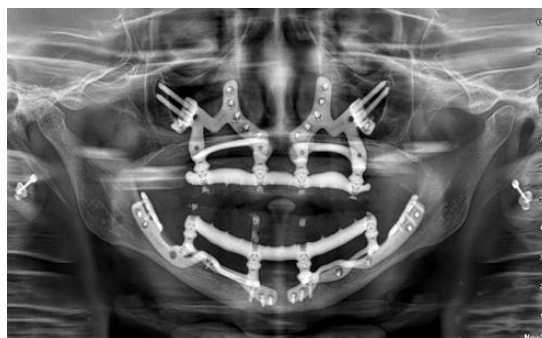


Figure 11: Pano x-ray follow up 2 years.

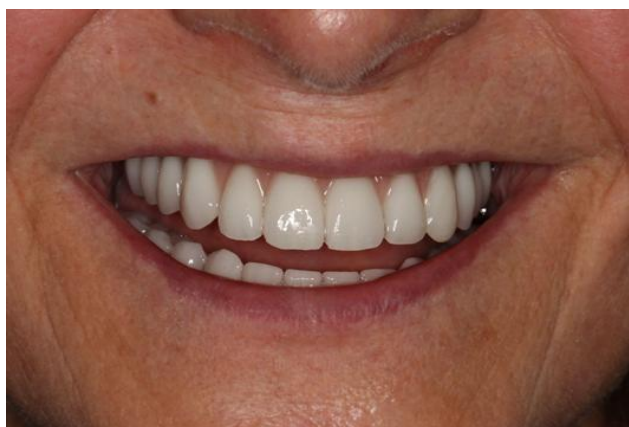

Figure 12: Final restoration.

Conclusion

Individualized dental implants provide a viable alternative for rehabilitating severe maxillary and mandibular atrophies without bone grafting. These implants are not a return to conventional subperiosteal designs but are based on well-established surgical principles, manufactured in compliance with medical device regulations. With continued advancements, individualized implants are becoming a primary choice for cases of extreme atrophy.

References

1. Brånemark PI, Zarb GA, Albrektsson T. (1985) Tissue-integrated prostheses: osseointegration in clinical dentistry. Quintessence Publishing.
2. Bedrossian E, Sullivan RM. Fixed implant rehabilitation for the edentulous patient: conventional and digital treatment approaches. Springer; 2021.
3. Parel SM, Triplett RG. (1990) Immediate fixture placement in the severely atrophic maxilla: a preliminary report. *J Prosthet Dent.* 64(5):639-44.
4. Maló P, de Araújo Nobre M, Lopes A, Ferro A, Gravito I. (2019) All-on-4 concept for full-arch rehabilitation of the edentulous maxilla: a clinical report on the medium (5 years) and long-term (10 years) outcomes. *Clin Implant Dent Relat Res.* 21(4):538-49.
5. Boyes-Varley JG, Howes DG, Lownie JF, Blackbeard GA. (2003) Surgical modifications to the Brånemark

- zygomaticus protocol in the treatment of the severely resorbed maxilla: a clinical report. *Int J Oral Maxillofac Implants.* 18(2):232-37.
6. Santos LMM, Figueiredo JLT, Coelho RPLM, Carvalho SDG, Martins MI. (2024) Comparison of Zygomatic Implants and Implantize Compact from Bone easy: A Finite Element Analysis for Bending and Safety Factor. *J Oral Med Dent Res.* 5(3):1-9.
 7. Santos LMM, Ciloto BHA, Figueiredo JLT, Coelho RPLM. (2024) Analyzing the Forces on Dental Implant with Exclusive Apical Fixation: A Critical Evaluation of Leverage and ISO 14801/2016 Testing Protocols. *J Oral Med Dent Res.* 5(3):1-9.