

## Combined Therapies in the Treatment of Temporomandibular Dysfunction with Degenerative Joint Disease Associated with Myofascial Pain and Bruxism

Susana Perdigoto<sup>1\*</sup>, João Adriano<sup>2</sup> and Eduardo Januzzi<sup>3</sup>

<sup>1</sup>DDM, MSc, PhD fellow Universidad Europea Madrid

<sup>2</sup>B.Sc. in Physiotherapy, post-graduate in TMD

<sup>3</sup>PhD- Dentist- Orofacial Pain Center of the Mater Dei Hospital, Belo Horizonte, Minas Gerais, Brazil

\***Corresponding author:** Susana Perdigoto, DDM, MSc, PhD fellow Universidad Europea Madrid

**Citation:** Perdigoto S, Adriano J, Januzzi E. Combined Therapies in the Treatment of Temporomandibular Dysfunction with Degenerative Joint Disease Associated with Myofascial Pain and Bruxism. J Orthop Study Sports Med. 2(1):1-23.

**Received:** November 23, 2024 | **Published:** December 05, 2024

**Copyright**© 2024 genesis pub by Perdigoto S et al. (CC BY-NC-ND 4.0 DEED. This is an open-access article distributed under the terms of the Creative Commons Attribution-Non Commercial-No Derivatives 4.0 International License. This allows others distribute, remix, tweak, and build upon the work, even commercially, as long as they credit the authors for the original creation.

### Abstract

#### Objectives

This study aims to evaluate the effects of sequential bicompartamental viscosupplementation (VS) of the temporomandibular joints (TMJ) combined with the use of a Michigan splint [1], dry needling (DN), physiotherapy (PHT) [2-4], and the control of awake bruxism (AB) and sleep bruxism (SB). The focus is on restoring joint biomechanics, controlling degenerative joint disease, treating myofascial pain, and facilitating the patient's functional recovery.

#### Materials and Methods

A 60-year-old patient diagnosed with myofascial pain with referral, osteoarthritis, osteoarthrosis, and presumed non-reducing disc displacement in both TMJ, as well as possible primary or idiopathic AB and SB [5-7], was treated using a multidisciplinary approach tailored to address the various diagnoses.

The patient underwent monthly evaluations before and after VS, including assessments of joint noise, measurement of the range-of-motion (ROM) using a millimeter ruler (Therabite), and pain assessment using the visual analog scale (VAS) [8]. Complementary diagnostic tests, such as orthopantomography and cone beam computed tomography (CBCT), were conducted prior to the treatment protocol and again six months post-treatment. Myofascial pain was managed using DN and PHT [9].

Bruxism control for both SB and AB were managed with PHT. The approach to AB included counseling and the recommendation to use a mobile application "desencoste seus dentes", to increase awareness of AB (10). For SB, in addition to PHT, a Michigan splint was fabricated [11,12].

Osteoarthritis and osteoarthrosis were managed using a sequential protocol of hyaluronic acid (HA) injections. Medium molecular weight HA (Osteonil Plus, TRB Pharma) was injected into the upper compartment of the TMJ, while low molecular weight HA (Hyalart, Bagó Pharma) was alternated with medium molecular weight HA (Osteonil Plus, TRB Pharma) in the lower compartment of both TMJs. Injections were administered monthly for four months [13,14].

After each VS session and during the following week, PHT was administered, and the patient was given instructions for home exercises [15].

### Results

Myofascial pain was effectively controlled, with a reduction from intense pain to an absence of pain by the end of the treatment. Control of AB was achieved, with an absence of SB symptoms observed.

Evident structural improvement in the shape and volume of the mandibular head in both TMJs, as demonstrated by CBCT. Significant increase in ROM, from an initial ROM of 30 mm to a final ROM of 44 mm, with no joint noise or pain. There was also improvement in daily functional activities, such as eating and speaking. The patient continues to undergo monthly PHT reassessments and semiannual medical evaluations.

### Conclusions

Multidisciplinary therapy, incorporating sequential VS with HA in both joint compartments, combined with a Michigan splint, PHT, and control of AB and SB, was effective in treating myofascial pain and in managing osteoarthritis and osteoarthrosis.

### Keywords

Viscosupplementation; Hyaluronic acid; Temporomandibular joint; Osteoarthritis; Osteoarthrosis; Myofascial pain; Bruxism; Dry needling; Physiotherapy.

## Brief Summary

Clinical case report of a patient with joint and muscular temporomandibular disorder (TMD) treated through an interdisciplinary approach, based on diagnoses obtained using the Diagnostic Criteria for

Temporomandibular Disorders (DC/TMD).

## Study impact

Joint and muscular TMD is highly prevalent. The use of minimally invasive, interdisciplinary therapies offers effective solutions for conditions that significantly reduce patients' quality of life.

## Abbreviations

- **AB** – Awake Bruxism
- **BV** – Bruxism Vigilance
- **CBCT** – Cone Beam Computed Tomography
- **CBT** – Cognitive-Behavioral Therapy
- **DC/TMD** - Diagnostic Criteria for Temporomandibular Disorders
- **DN** – Dry Needling
- **EMA** – Ecological Momentary Assessment
- **HA** – Hyaluronic Acid
- **LTB4** – Leukotriene B4
- **OR** – Odds Ratio
- **PAF** – Platelet-Activating Factor
- **PGE2** – Prostaglandin E2
- **PHT** – Physiotherapy
- **PRF** – Platelet-Rich Fibrin
- **PRP** – Platelet-Rich Plasma
- **RDC/TMD** – Research Diagnostic Criteria for Temporomandibular Disorders
- **ROM** – Range-of-Motion
- **SAH** – Sodium Hyaluronate
- **SB** – Sleep Bruxism
- **TMD** – Temporomandibular Disorder
- **TMJ** – Temporomandibular Joint
- **VAS** – Visual Analog Scale
- **VS** – Viscosupplementation

## Introduction

The temporomandibular joints (TMJ) differ from other synovial joints in structure. Their articular surfaces are not covered by hyaline cartilage but by fibrocartilage, with a fibrocartilaginous disc positioned between these surfaces. This disc compensates for joint incongruities and facilitates both sliding and rotational movements between the bony components [16].

The disc consists of three layers of fibrocartilage. The articular surface, along with the periosteum, produces fibrocartilage to withstand loads and possesses unique reparative and adaptive properties [17]. The TMJ plays a crucial role in chewing, jaw mobility, and verbal and emotional expression [18].

Temporomandibular disorders (TMD) have a global prevalence of 5% to 12% and encompass various conditions that may result in symptoms of orofacial pain and functional limitations [18].

TMD encompasses various structural and functional conditions that affect the TMJ, masticatory muscles, and associated structures [5]. The etiology of TMD is multifactorial, potentially linked to dental, medical, traumatic, psychosocial, or genetic factors [19,20]. Patients often experience physical and functional limitations, along with psychological discomfort and a reduced quality of life [21,22].

Using the DC/TMD tool, possible diagnoses for muscle dysfunction include myalgia, myofascial pain, and referred myofascial pain. The diagnosis of myofascial pain has a sensitivity of 0.84 and a specificity of 0.95 and is characterized by a history of regional pain within the past 30 days, which is exacerbated by mandibular movement during function or parafunction. The examination involves palpation to confirm the painful anatomical area, with the patient identifying the pain as familiar.

The diagnosis of referred myofascial pain has a sensitivity of 0.85 and a specificity of 0.98. It is determined through palpation, with the pain perceived outside the anatomical boundaries of the muscle being evaluated [10].

According to the 2014 DC/TMD, the diagnostic criteria for TMJ joint diseases (osteoarthritis and osteoarthrosis) include joint noise, crepitus, and limited mouth opening, with confirmation via CBCT. This imaging examination is used to detect morphological changes, such as subchondral pseudocysts in the condyle, along with evidence of erosions, sclerosis, flattening, and osteophytes in the articular eminence. In osteoarthritis, joint pain is also present among the patient's symptoms [10].

In 2018, Lobbezoo et al. proposed an evaluation system aimed at validating a new classification of bruxism. In this model, the diagnosis of possible SB and AB is based solely on self-report. The diagnostic of probable SB and AB is determined through self-report combined with clinical inspection. Definitive SB is diagnosed through self-report, clinical inspection, and polysomnography (preferably combined with audio/video recordings), while definitive AB requires self-report, clinical inspection, and electromyography (preferably combined with additional evaluation methodologies or new ecological assessment technologies, such as ecological momentary assessment [EMA]) [23].

Various approaches exist for the treatment of referred myofascial pain. In individuals diagnosed with referred myofascial pain using the DC/TMD criteria, Joanna Cuq et al. applied mobilization techniques to the masseter, temporalis, sternocleidomastoid, and bilateral digastric muscles. Following the application of these techniques, they concluded that PHT incorporating soft tissue mobilization appears effective in relaxing the masticatory muscles in patients with TMD [24].

Antoon de Laat et al. demonstrated that a conservative approach involving counseling and PTH results in significant improvements in pain parameters and jaw function in patients with myofascial pain [25].

Manipulative techniques targeting peripheral nociceptive trigger points can alleviate chronic pain symptoms and reduce the need for medication in acute situations. An interdisciplinary approach that

incorporates both pharmacological and non-pharmacological strategies can decrease analgesic consumption and alleviate symptoms of myofascial dysfunction in patients with chronic conditions [26].

César Fernández-de-Las-Peñas et al. propose that trigger-point DN can reduce central nervous system excitability by diminishing peripheral nociception, lowering neuronal activity in the dorsal horn, and modulating pain-related brain regions. The effects are moderate to small and are primarily observed in the short term. Consequently, it is suggested that DN be integrated into the current pain neuroscience paradigm, in combination with pain neuroscience education, therapeutic exercise, and manual therapy [9].

The use of medications such as gabapentinoids and tricyclic antidepressants has shown a positive pharmacotherapeutic response in the management of persistent myofascial pain, even in more severe cases [27,28].

In approaching osteoarthritis, it is essential to consider that this condition is primarily characterized by degenerative changes in the articular cartilage, leading to cartilage loss and alterations in the subchondral bone. Osteoblasts exhibit several metabolic changes that can disrupt normal cell metabolism and signaling, potentially resulting in an altered extracellular matrix composition. Prostaglandins play a critical role not only in joint physiology but also in the pathogenesis of joint disorders. Furthermore, subchondral osteoblasts have been found to synthesize leukotriene B<sub>4</sub>, suggesting a role for leukotrienes in bone remodeling associated with osteoarthritis [29].

According to Tsai CM et al., CBCT is superior to simple radiographic modalities for diagnosing bone degenerative features of the TMJ, particularly in cases where standard radiographs are indeterminate. CBCT demonstrates greater reliability, sensitivity, and specificity, and is therefore recommended as an effective tool for identifying TMJ osteoarthritis [30-33].

Nicolas Bazan et al. conducted a study to identify levels of prostaglandin E<sub>2</sub> (PGE<sub>2</sub>), leukotriene B<sub>4</sub> (LTB<sub>4</sub>), and platelet-activating factor (PAF) and found a strong correlation between these pain and inflammation mediators and an index of clinical joint pathology [34].

Wang X et al. suggest that intra-articular injection of HA may reduce synovitis and improve the internal environment of the TMJ [35]. Hirota measured the effects of sodium hyaluronate on the levels of arachidonic acid metabolites and cytokines related to TMJ osteoarthritis symptoms. According to Hirota, the injection of sodium hyaluronate (SAH) into the upper compartment of the TMJ significantly reduced the mean levels of leukotriene C<sub>4</sub>, 6-keto prostaglandin F<sub>1-α</sub>, prostaglandin F<sub>2-α</sub>, and interleukin 1-β, resulting in a statistically significant reduction in pain and joint noise. Mouth opening was among the parameters evaluated by Hirota, showing the most substantial improvement with HA treatment [36].

Iturriaga et al. describe that HA injections help regulate inflammatory processes associated with TMJ degenerative changes and have studied the role of mediators in the plasminogen and nitric oxide activating system [6]. In a retrospective study, Haibin Sun et al. found that HA injections into the upper and lower joint spaces led to improvements in the clinical dysfunction index, increased mouth opening

amplitude, and reduced pain levels. However, no reduction in condylar bone alterations was observed in CBCT evaluations [8].

Januzzi et al. implemented a treatment protocol in patients diagnosed with disc displacement and/or osteoarthritis, evaluated using the Research Diagnostic Criteria for Temporomandibular Disorders (RDC/TMD). These patients received four monthly injections of low or medium molecular weight HA. Pain, mandibular function, CT imaging, magnetic resonance imaging, and quality of life were assessed immediately after the procedure and again six months later. Resolution of intra-articular effusion and improvements in disc morphology were observed in most patients. This VS protocol, alternating cycles of HA with different molecular weights, led to reduced pain and symptoms associated with internal TMJ disorders, as well as improved patient quality of life [13].

According to Cheng Li et al., HA injections into both compartments of the TMJ are effective for treating osteoarthritis with disc displacement without reduction. Injection of HA into the lower joint space appears to promote better remodeling and improved jaw function [37].

Cheng Li et al., in a study involving 126 patients, concluded that injections into both joint spaces of the TMJ are effective for treating TMD with degenerative changes. However, injection into the lower joint space appears to have a greater reparative effect, promoting condylar remodeling and functional improvement [38].

In a meta-analysis, Chunjie Li et al. compared the effects of HA injection in the upper joint compartment with injections in both joint compartments - or in the lower compartment. Their findings indicate that the injection technique targeting the lower TMJ space, or both compartments, has a superior effect compared to injection solely in the upper joint space [39].

The meta-analysis demonstrated that the inferior or dual-space injection technique significantly increases maximum mouth opening ( $p=.0001$ ) and reduces pain intensity in the temporomandibular area by an average of 9.01 mm on the visual analog scale ( $p=.0001$ ), compared to the upper space injection technique. Additionally, the procedure is considered completely safe [39].

Regarding the management of AB and SB, conservative treatments have been documented. Parafunctional habits and bruxism are considered risk factors for TMD, with an odds ratio (OR) of 4.8. Psychophysiological theory identifies stress as a determining factor in the development of bruxism and myofascial pain [40].

A correct diagnosis of the causes of bruxism is essential for identifying its origins. Although many of the variables associated with bruxism cannot be modified through prophylactic or therapeutic measures, Türp and Kuhn recommend a patient-centered 8 approach to managing SB, emphasizing self-observation, muscle relaxation, and the use of a stabilization splint (Michigan splint) [41].

Smartphone-assisted monitoring of masticatory muscle activity may have clinical relevance, potentially enabling associations between excessive muscle activity, bruxism, dysfunction, and pain that warrant

further investigation and treatment through biofeedback. Mobile applications, such as Bruxapp® and Desencoste seus Dentes®, can assist in the management of AB [11,42-44].

Daytime biofeedback training aims to increase awareness of AB without disrupting sleep patterns or causing associated side effects [45-47]. DN, PHT, relaxation exercises, and cognitive-behavioral therapy (CBT) have also been reported as effective methods for managing AB [47].

## **Clinical case description**

### **Patient data**

**Patient:** AMGC, Age: 60 years

**Background:** Generally healthy; history of a motorcycle accident in youth, resulting in trauma to the left TMJ.

During the initial consultation, the patient reported orofacial and cervical pain, accompanied by limited mouth opening (30 mm) that had progressively worsened, restricting chewing ability. Additionally, the patient exhibited TMJ noise with crepitus and reported pain in the left joint. At the patient's request, no analgesics or other pain-modulating medications were prescribed.

## **Materials and Methods**

The patient provided written informed consent for the medical treatment procedure and for the scientific publication of the obtained results.

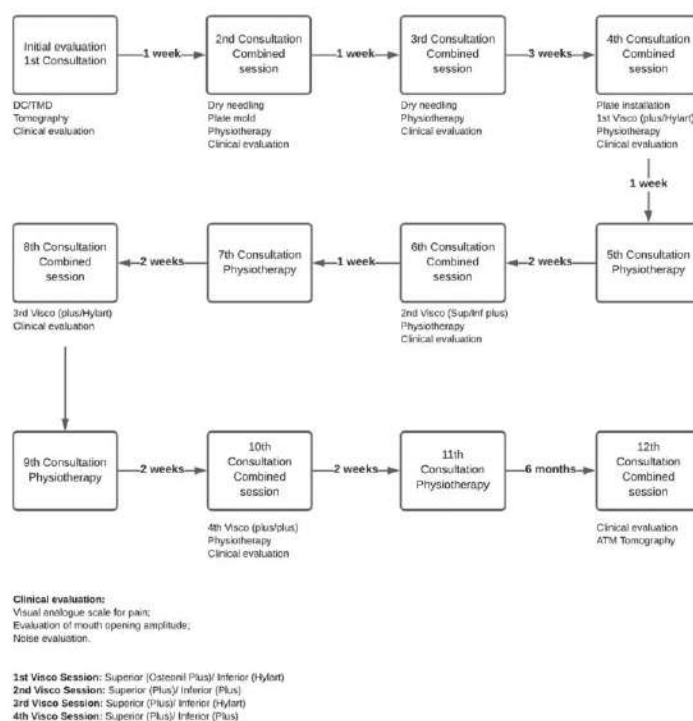
A clinical evaluation was conducted based on the DC/TMD criteria [10], yielding the following diagnoses: Myofascial pain reported in the muscles, including the superficial and deep masseters, temporalis, posterior digastric, sternocleidomastoid, and suboccipital muscles. Joint pain in the left TMJ was recorded, with a score of 10 on the VAS, indicating maximum pain severity. A probable diagnosis of osteoarthritis in the right joint and confirmed osteoarthritis in the left joint was also established.

The patient's initial ROM was 30 mm. Mouth opening and closing movements were performed without deviations but were accompanied by bilateral coarse crepitus. The end feel upon maximum opening was firm and unyielding.

The confirmation of degenerative TMJ pathology was conducted using 3D CBCT imaging with Papaya Plus® equipment from Genoray, providing a resolution of 75 microns, and analyzed using Triana software. The patient exhibited osteophytes, erosion, abrasion, subchondral pseudocysts, and destruction of the mandibular head in both TMJs, with more pronounced findings in the left TMJ [48].

The patient presents with type 3 and 4 tooth wear, as classified by Hasselkvist in 2016 [49], and reports grinding his teeth during both wakefulness and sleep. Dental erosion consistent with this description was observed. He has no associated pathologies, comorbidities, or sleep apnea. Based on this assessment and the 2018 consensus, the patient was determined to have idiopathic or primary SB and AB [23].

A multidisciplinary treatment plan was established and implemented [50-53], as outlined in the flowchart shown in (Figure 1).



**Figure 1:** Treatment flowchart.

The PTH treatment was administered by a single physiotherapist trained in pain management and TMD therapy, with a frequency of one session per week until September of the same year.

The PHT protocol included TMJ distraction techniques combined with ventilatory training, emphasizing diaphragmatic breathing, and stretching of the masticatory [54], cervical, and 11 shoulder girdle muscles. This was followed by exercises targeting the deep cervical muscles [55-57].

The PTH intervention details are presented in (Table 1).

Intervention	Description	Duration
Stretching and mobilization of the masticatory, cervical muscles, and shoulder girdle.	<p>Patient positioned in supine, with diaphragmatic breathing training.</p> <p>Contraction/stretching, soft tissue mobilization, and trigger point compression were applied, focusing on the masseter, anterior temporalis, and cervical muscles, such as the upper trapezius and sternocleidomastoid muscles bilaterally. Intraoral massage and ischemic compression of trigger points were performed using gloves.</p> <p>Passive/active intra- and extra-oral exercises were performed, targeting all masticatory muscles and the muscles of the shoulder girdle.</p> <p>Craniocervical flexion exercises focused on recruiting deep cervical flexor muscles were performed, significantly increasing the cross-sectional area of the longus colli muscle <sup>(55)</sup>.</p>	1 hour

**Table 1:** Physical therapy intervention.



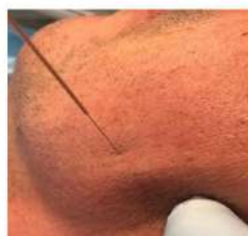Two initial DN sessions were conducted immediately before the first two physiotherapy consultations, targeting the trigger points of muscles with referred myofascial pain. In the first session, DN was applied to the masseter, temporalis, and suboccipital muscles using 40 mm disposable, sterile acupuncture needles with ethylene oxide sterilization and uncoated copper handles, as shown in (Figure 2).



**Figure 2:** 40 mm acupuncture needles.

The superficial portion of the masseter muscle causes referred pain to the eyebrows, upper jaw, anterior part of the eyebrow, jaw, and upper or lower molars, while the deep portion refers pain to the deeper areas of the ear and toward the TMJ region.

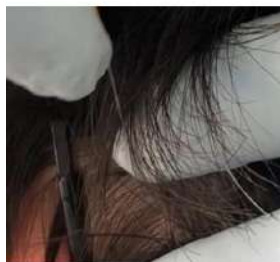
The following puncture technique was used: After positioning the patient supine, the muscle was cleaned with 70% alcohol, and the skin was disinfected with 4% chlorhexidine. Using flat palpation, the muscle was palpated to locate trigger points within taut bands, eliciting familiar referred pain in the ear area, outside the palpated muscle. The needle was then inserted perpendicularly to the skin, directed toward the muscle body and the trigger point (Figure 3). In this region, the technique is straightforward.



**Figure 3:** DN of the masseter muscle.

**Note:** The needle is inserted perpendicularly to the skin, targeting the body of the muscle at the trigger point.

The temporalis muscle causes referred pain perceived deep in the temporoparietal region and inside the head, often manifesting as headaches and jaw pain. For the puncture technique, the patient was positioned supine. The muscle was identified through flat palpation, and the needle was controlled with the index fingers, inserted perpendicularly into the skin toward the temporal fossa. During the puncture of this muscle, it is essential to identify and avoid the superficial temporal artery (Figure 4).

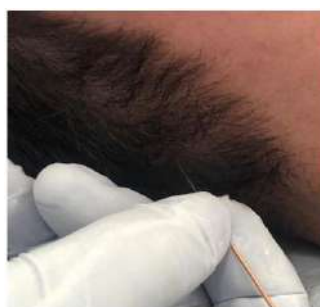


**Figure 4:** Puncture of the temporalis muscle.

The suboccipital muscles refer to pain that is deeply perceived from the occiput to the orbital region, with characteristics similar to tension headaches.

Only the inferior oblique muscle of the head was punctured due to the proximity of the vertebral artery above the atlas arch. The patient was positioned laterally. The muscle was punctured at the midpoint between the transverse process of C1 and the spinous process of C2. The needle was inserted perpendicularly to the skin, directed into the medial portion of the muscle and angled toward the contralateral eye, with a slight cranial-medial orientation.

**Precautions:** Palpate and isolate the muscle, avoiding excessive cranial or lateral angulation to prevent inadvertent penetration of the vertebral artery or foramen magnum. The suboccipital puncture technique is illustrated in Figure 5.

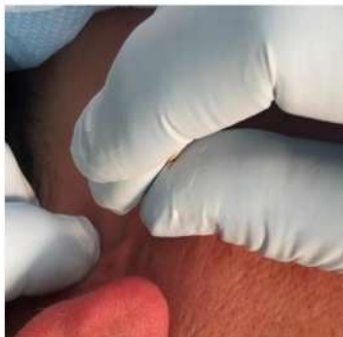

**Figure 5:** DN of the suboccipital.

In the second consultation, DN was performed on the posterior bellies of the digastric and sternocleidomastoid muscles (Figure 6).

For accessing the posterior belly of the digastric muscle, the safest location is at its insertion at the apex of the mastoid, directed toward the transverse process of the atlas. When needling the posterior belly, it is essential to avoid the external jugular vein.

To access the posterior belly muscle of the digastric, the location of least risk is at the insertion at the vertex of the mastoid in the direction of the transverse process of the atlas. In posterior belly, it is necessary to avoid the external jugular vein.

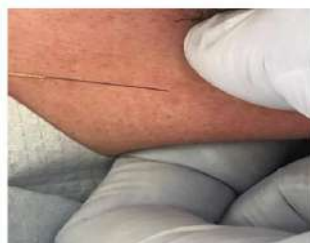

**Figure 6:** DN of the posterior belly of the digastric at the vertex of the mastoid.

The sternal portion of the sternocleidomastoid muscle may refer to pain at the cranial apex, occiput, cheek, eye, throat, and sternum, while the clavicular portion refers to pain in the forehead and at the depth of the ear, often resulting in frontal headaches and ear pain.

For the DN procedure, the patient is positioned supine. The clavicular and sternal portions of the muscle are identified and isolated using pinch palpation of the muscle belly, following identification of the carotid artery. In this case, only the sternal portion was punctured.

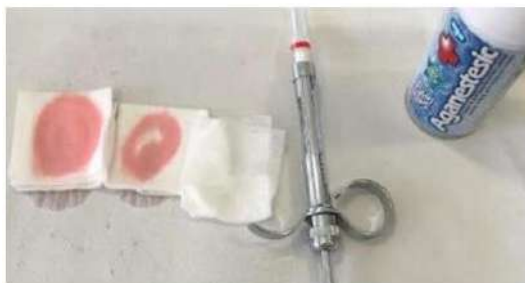The needle was inserted perpendicularly to the skin, with the clinician's finger positioned to guide the insertion from front to back (Figure 7). The carotid artery, located medially, is an anatomical structure that poses a risk during this procedure.



**Figure 7:** DN of the sternal belly of the left ecom.

Counselling on bruxism vigilance (BV) was provided, including the recommendation to download the mobile application "desencoste seus dentes" [58-60].

In early September, a Michigan splint was placed, and a VS protocol was initiated. All injections were administered by a single experienced operator, following this protocol: Skin disinfection with alcohol and 4% chlorhexidine [61,62], skin cooling with Aganestestic<sup>®</sup> cold 15 ice spray [63], and intra-articular anesthesia with 0.3 cc of mepivacaine (without vasoconstrictor) per joint compartment (Figure 8).



**Figure 8:** Products and material used for disinfection and joint anesthesia.

Upper compartment: Injection of 1.2 ml of HA, Osteonil Plus<sup>®</sup>, administered monthly for four months (Figure 9). Access to the entry point of the upper compartment was achieved with the patient in maximum mouth opening. The preauricular depression was palpated to locate the upper bony landmark of the articular fossa on the temporal bone. This point was marked, serving as a reference for both the upper compartment entry and the lower compartment access point. A 12.7 mm insulin needle was used, with angulation directed superiorly/inferiorly and medially [39].

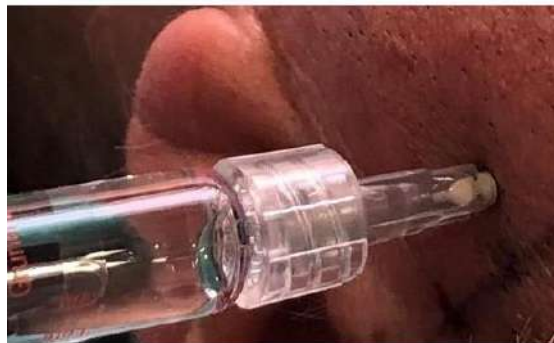

**Figure 9:** HA of medium molecular weight with double concentration.

Lower compartment: Access to the lower compartment was achieved with a controlled mouth opening of 10 mm. The condyle was palpated, and an initial anatomical point was marked on the skin at the highest location of the joint fossa in the preauricular depression. From this point, a line was drawn toward the corner of the eye. Along this line, additional markings were made at a 5 mm and 7 mm intervals below the initial point. The entry site for the lower compartment was located along this line.

The needle was inserted laterally and cranially until it contacted the condyle (second anatomical point), then retracted by 2 mm, and rotated distally and medially to a depth of 20 mm using a 24G, 25 mm needle [1].

Intra-articular injection of 1 ml of low molecular weight HA, Hyalart<sup>®</sup>, was administered, alternating with HA containing mannitol (Osteonil Plus<sup>®</sup>), for four months [2] (Figure 10 and 11).



**Figure 10:** Low molecular weight HA injection



**Figure 11:** 10 mm ROM control.

Following each intervention and in the subsequent week, the patient attended a PHT session. He continued to perform prescribed exercises at home and used a splint custom built in the clinic by the operator who administered the VS, with the opening achieved after each injection. The patient wore the Michigan splint throughout the treatment period, with adjustments and evaluations conducted at 1 month, 3 months, and 6 months after initial placement.

During each consultation, the amplitude of mouth opening was recorded at the beginning and immediately following the VS procedure. Joint pain and noise were also documented.

### **Results**

The effectiveness of the treatment protocol was assessed by the degree of mandibular head remodeling observed post-treatment, while patient functionality was evaluated through measurements of mouth opening amplitude and pain reduction.

Absence of joint pain and myofascial pain was achieved, with a final ROM 44 mm (Table 2). Joint remodeling and repair were observed in both TMJs, with significant regularization of the mandibular head, particularly in the left joint.

The right TMJ also exhibited remodeling and significant improvement.

Time	T1 Without VS	T2 1ST VS	T3 2SD VS	T4 3TD VS	T5 4TH VS	6 months T6 Without VS
ROM (start)	30 mm	38 mm	40 mm	42 mm	42 mm	44mm
ROM (end)	35 mm	40 mm	42 mm	45 mm	45mm	44mm

**Table 2:** Active mouth opening range (ROM).

Evolution of ROM following the first visit with sequential VS protocol and final ROM at 6-month reassessment.

There was an increase of 14 mm in ROM from the first consultation (T1) to the final reassessment (T6).

Both active and passive ROM were expanded by 14 mm, now achieved without bilateral joint pain or myofascial pain (Table 3).

Time	Beginning (T1)	(T2)	(T3)	(T4)	(T5)	6 months Re-evaluation (T6)
Myofascial pain	10	5	1	0	0	0

**Table 3:** Evolution of myofascial pain (VAS).

Assessment of myofascial pain progression with the multidisciplinary protocol during treatment and 6-month post-treatment reassessment.

There was also a positive improvement in joint noise (Table 4).

Time	T1	T2	T3	T4	T5	T6
Right TMJ	Coarse crackling	Moderate crackling	Absence of crackling	Absence of crackling	Absence of crackling	Absence of crackling
Left TMJ	Coarse crackling	Coarse crackling	Moderate crackling	Absence of crackling	Absence of crackling	Absence of crackling

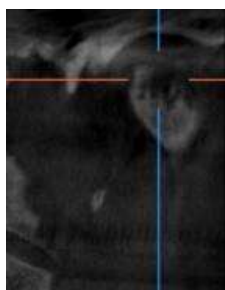
**Table 4:** Assessment of the crepitus progression over the course of treatment.

	T1	T2	T3	T4	T5	T6
Right TMJ	0	0	0	0	0	0
Left TMJ	10	7	1	0	0	0

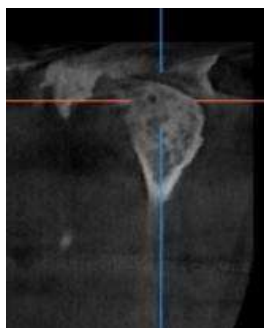
**Table 5:** Assessment of the joint pain progression over the course of treatment.

Absence of pain following the second bi-compartmental intra-articular injection.

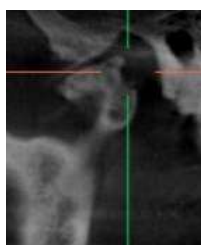After the final month of the protocol, the patient continued physical therapy sessions every 15 days. Six months later, a final CBCT was performed, and the patient attended monthly physical therapy maintenance appointments. Figures 12 to 23 illustrate the progression of results, displaying initial CBCT images of both joints and the initial mouth opening, as well as final CBCT images taken six months after the completion of the protocol.



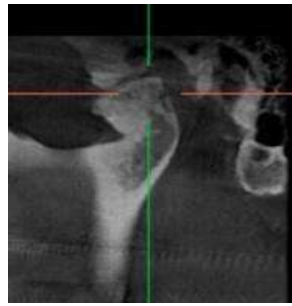**Figure 12:** T1 left TMJ  
Osteoarthritis with morphological alteration.



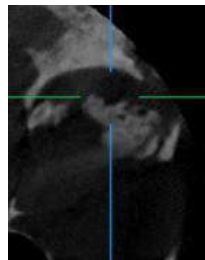
**Figure 13:** T6 left TMJ.  
6 months after the end of the protocol, with gain in volume and shape in the mandible head.



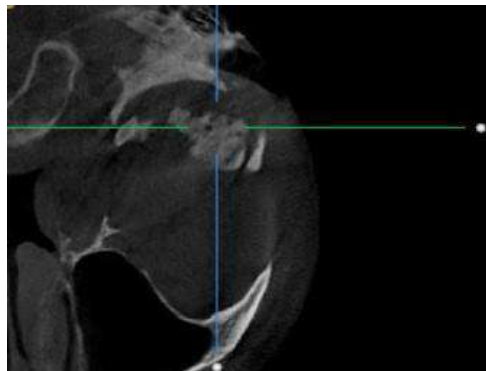
**Figure 14:** T1 left TMJ.



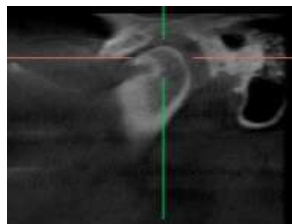
**Figure 15:** T6 left TMJ end-distal closure.



**Figure 16:** T1 left TMJ  
Sub-chondral pseudocysts.

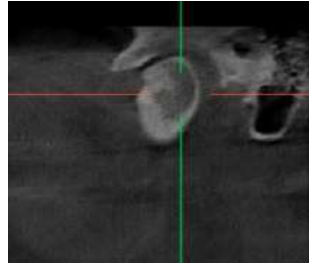


**Figure 17:** T6 left TMJ  
Pseudocysts closure.

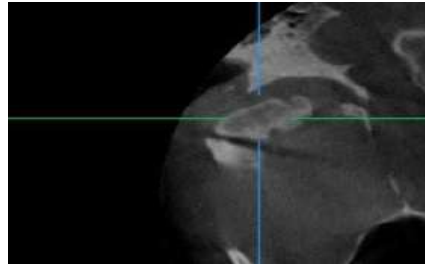


**Figure 18 :** T1 right TMJ  
TMJ osteophyte.

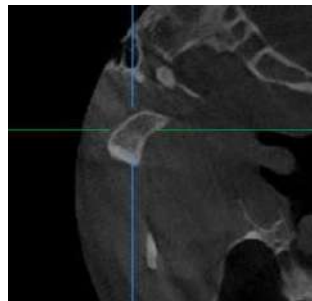




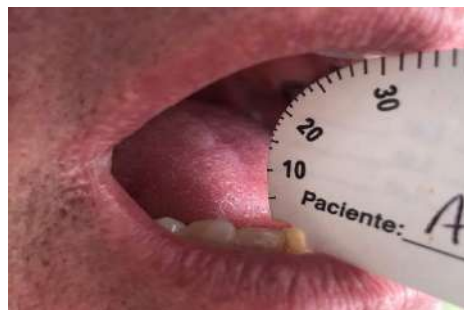**Figure 19:** T6 right TMJ  
Osteophyte-free right TMJ end, shape, and volume gain.



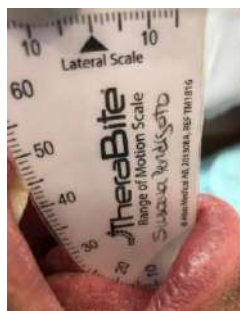**Figure 20:** T1 right TMJ  
Sub-chondral pseudocysts.



**Figure 21:** T6 right TMJ  
Cortical closed.



**Figure 22:** T1 initial ROM.



**Figure 23:** T6 final ROM  
14 mm ROM increase.

## Discussion

The treatment plan developed and implemented was multidisciplinary and primarily conservative, tailored to address the specific pathologies presented by the patient.

The patient's primary complaint was joint pain in the left TMJ due to osteoarthritis, along with a restricted range of mouth opening that impaired chewing and feeding. CBCT confirmed osteoarthritis in the left TMJ and osteoarthrosis in the right TMJ. Additionally, the patient exhibited myofascial pain in both the superficial and deep masseter muscles, the temporalis muscle, the posterior bellies of the digastric, the sternocleidomastoid, and the suboccipital muscles, as previously noted. Idiopathic AB and SB were also diagnosed.

To address myofascial pain, an initial treatment plan incorporating a pharmacological protocol along with PHT and DN techniques was proposed. However, at the patient's request to avoid pharmacological therapy, only PHT and DN were administered.

Given the chronic nature of the pain, which had persisted for several years, it was explained to the patient that the prognosis was uncertain, particularly in the absence of pain control medication. Nonetheless, the outcome exceeded our expectations, as the combination of PHT and DN proved to be effective in managing pain.

The VS protocol used in this clinical case was like that adopted in the study by Januzzi et al [13]. In addition to this VS protocol, immediate PHT and home exercises were implemented to improve joint mobility and enhance the lubricating effect of HA.

Malgorzata Litwiniuk et al. stated that, under physiological conditions, the activation of immune cells is essential for effective wound healing. In acute wounds, small, low- molecular-weight hyaluronate fragments that accumulate at the injury site stimulate the immune system to address disruption in tissue integrity [64].

CD44 receptor signaling within the wound environment induces fibroblast migration from surrounding tissues to the injured area. It is important to note that neither CD44 nor HA alone can induce cell migration or promote wound healing; rather, an interaction between HA and CD44 is essential to activate this process. The binding ability of hyaluronate particles to the CD44 receptor

depends on their molecular size, with evidence showing that the binding affinity of hyaluronates to CD44 increases as molecular weight rises.

Studies have shown that high molecular weight HA exhibits anti-inflammatory properties and has a cytoprotective effect by reducing apoptosis and oxidative stress [64]. For this reason, Osteonil Plus®, containing a double concentration of HA and combined with mannitol, was used, along with low molecular weight Hyalart® applied to the lower joint compartment. This protocol, in combination with physiotherapy, aimed to enhance joint lubrication and repair, improve joint dynamics, reduce pain, increase mouth opening amplitude, and minimize noise.

The approach used to manage AB included counseling, PHT, habit awareness techniques, and the use of the mobile application "Desencoste seus Dentes" [11,42,43]. Additionally, a Michigan splint was employed to control SB.

The evaluation of results was based on both clinical outcomes and CBCT imaging. The patient's clinical progress was considered positive, and changes observed in the CBCT images 11 months after the initial consultation demonstrated clear morphological improvement in the joint.

In CBCT images, it is not possible to visualize the articular fibrocartilage. Consequently, we believe that, given the injuries observed, there is likely no remaining articular fibrocartilage in the left TMJ. Since biopsy is not ethically feasible, we assume that, histologically, the tissue obtained at the end of treatment is more fragile, albeit healthy and without lesions. The patient was therefore advised to continue monthly physiotherapy, use a Michigan splint at night, and monitor parafunctional habits. Additionally, annual CBCT monitoring was recommended, with instructions to repeat the treatment protocol if the condition worsens.

According to recent studies, arthrocentesis of both TMJs could have been performed to achieve joint lavage [65], thereby reducing inflammatory mediators. Additionally, biosupplementation with blood-derived substrates, such as injectable platelet-rich fibrin (PRF) or platelet-rich plasma (PRP), could also be considered [66, 67].

The results achieved exceeded initial expectations, attributable to both the interdisciplinary treatment plan and the patient's adherence to the entire treatment regimen.

The authors declare that they have no conflicts of interest, as stated in the completed declaration form.

## Conclusions

The objective of this study was to evaluate the effects of sequential viscosupplementation in both TMJ compartments [13,67], in combination with the use of a Michigan splint [1], dry needling, physiotherapy [2-4], and bruxism management during wakefulness and sleep, on reestablishing joint

biomechanics, controlling degenerative joint disease and myofascial pain, and achieving optimal functional recovery.

We found that sequential viscosupplementation with HA in both joint compartments, combined with conservative treatment and management of sleep and wake bruxism, was effective in treating myofascial pain and in controlling osteoarthritis and osteoarthrosis of the TMJ.

## References

1. Kuzmanovic Pfcier J, Dodic S, Lazic V, Trajkovic G and Milic N et al. (2017) Occlusal stabilization splint for patients with temporomandibular disorders: Meta-analysis of short- and long-term effects. PLoS One. 12(2): e0171296.
2. Armijo-Olivo S, Pitance L, Singh V, Neto F and Thie N et al. (2016) Effectiveness of Manual Therapy and Therapeutic Exercise for Temporomandibular Disorders: Systematic Review and Meta-Analysis. Phys Ther. 96(1):9-25.
3. Paço M, Peleteiro B, Duarte J, Pinho T. (2016) The Effectiveness of Physiotherapy in the Management of Temporomandibular Disorders: A Systematic Review and Meta-analysis. J Oral Facial Pain Headache. 30(3):210-20.
4. Cuenca-Martínez F, Herranz-Gómez A, Madroñero-Miguel B, Reina-Varona Á and La Touche R et al. (2020) Craniocervical and Cervical Spine Features of Patients with Temporomandibular Disorders: A Systematic Review and Meta-Analysis of Observational Studies. J Clin Med. 9(9).
5. Schiffman E, Ohrbach R, Truelove E, Look J and Anderson G et al. (2014) Diagnostic Criteria for Temporomandibular Disorders (DC/TMD) for Clinical and Research Applications: recommendations of the International RDC/TMD Consortium Network\* and Orofacial Pain Special Interest Group†. J Oral Facial Pain Headache. 28(1):6-27.
6. Ohrbach R, Dworkin SF. (2016) The Evolution of TMD Diagnosis: Past, Present, Future. J Dent Res. 95(10):1093-101.
7. Skeie MS, Frid P, Mustafa M, Aßmus J and Rosén A. (2018) DC/TMD Examiner Protocol: Longitudinal Evaluation on Interexaminer Reliability. Pain Res Manag. 2018:7474608.
8. Montalvo C, Finizia C, Pauli N, Fagerberg-Mohlin B and Andréll P. (2020) Impact of exercise with TheraBite device on trismus and health-related quality of life: A prospective study. Ear Nose Throat J. 145561320961727.
9. Fernández-de-Las-Peñas C, Nijs J. (2019) Trigger point dry needling for the treatment of myofascial pain syndrome: current perspectives within a pain neuroscience paradigm. J Pain Res. 12:1899-911.
10. DE PROENÇA LS, CHINEM LAS, TEMPOROMANDIBULAR HDA. FACSETE–FACULDADE SETE LAGOAS.
11. Manfredini D, Bracci A, Djukic G. (2016) BruxApp: the ecological momentary assessment of awake bruxism. Minerva Stomatol. 65(4):252-5.
12. Guaita M, Högl B. (2016) Current Treatments of Bruxism. Curr Treat Options Neurol. 18(2):10.
13. Fonseca R, Januzzi E, Ferreira LA, Grossmann E and Carvalho ACP, et al. (2018) Effectiveness of Sequential Viscosupplementation in Temporomandibular Joint Internal Derangements and Symptomatology: A Case Series. Pain Res Manag. 2018:5392538.
14. Liu Y, Wu JS, Tang YL, Tang YJ and Fei W, et al. (2020) Multiple Treatment Meta-Analysis of Intra-Articular Injection for Temporomandibular Osteoarthritis. J Oral Maxillofac Surg. 78(3): 373.e1-e18.
15. Shimada A, Ishigaki S, Matsuka Y, Komiyama O and Torisu T et al. (2019) Effects of exercise therapy on painful temporomandibular disorders. J Oral Rehabil. 46(5):475-81.
16. Sava A, Scutariu MM. (2012) Functional anatomy of the temporomandibular joint (I). Rev Med Chir Soc

- Med Nat Iasi. 116(3):902-6.
17. Stocum DL, Roberts WE. (2018) Part I: Development and Physiology of the Temporomandibular Joint. *Curr Osteoporos Rep.* 16(4):360-8.
  18. Ahmad M, Schiffman EL. (2016) Temporomandibular Joint Disorders and Orofacial Pain. *Dent Clin North Am.* 60(1):105-24.
  19. Bagis B, Ayaz EA, Turgut S, Durkan R and Özcan M. (2012) Gender difference in prevalence of signs and symptoms of temporomandibular joint disorders: a retrospective study on 243 consecutive patients. *Int J Med Sci.* 9(7):539-44.
  20. López Paños R, Ortiz-Gutiérrez RM, Chana Valero P, Felipe Concepción E. (2019) [Assessment of postural control and balance in persons with temporomandibular disorders: A systematic review]. *Rehabilitacion (Madr).* 53(1):28-42.
  21. Almoznino G, Zini A, Zakuto A, Sharav Y and Haviv Y et al. (2015) Oral Health-Related Quality of Life in Patients with Temporomandibular Disorders. *J Oral Facial Pain Headache.* 29(3):231-41.
  22. Roldán-Barraza C, Janko S, Villanueva J, Araya I and Lauer HC. (2014) A systematic review and meta-analysis of usual treatment versus psychosocial interventions in the treatment of myofascial temporomandibular disorder pain. *J Oral Facial Pain Headache.* 28(3):205-22.
  23. Lobbezoo F, Ahlberg J, Raphael KG, Wetselaar P and Glaros AG, et al. (2018) International consensus on the assessment of bruxism: Report of a work in progress. *J Oral Rehabil.* 45(11):837-44.
  24. Kuć J, Szarejko KD, Gołębiewska M. (2020) Evaluation of Soft Tissue Mobilization in Patients with temporomandibular Disorder-Myofascial Pain with Referral. *Int J Environ Res Public Health.* 17(24).
  25. De Laat A, Stappaerts K, Papy S. (2003) Counseling and physical therapy as treatment for myofascial pain of the masticatory system. *J Orofac Pain.* 17(1):42-9.
  26. Gandolfi M, Geroïn C, Valè N, Marchioretto F and Turrina A et al. (2018) Does myofascial and trigger point treatment reduce pain and analgesic intake in patients undergoing onabotulinumtoxinA injection due to chronic intractable migraine? *Eur J Phys Rehabil Med.* 54(1):1-12.
  27. Haviv Y, Rettman A, Aframian D, Sharav Y, Benoliel R. (2015) Myofascial pain: an open study on the pharmacotherapeutic response to stepped treatment with tricyclic antidepressants and gabapentin. *J Oral Facial Pain Headache.* 29(2):144-51.
  28. Haviv Y, Zini A, Sharav Y, Almoznino G, Benoliel R. (2019) Nortriptyline Compared to Amitriptyline for the Treatment of Persistent Masticatory Myofascial Pain. *J Oral Facial Pain Headache.* 33(1):7–13.
  29. Laufer S. (2003) Role of eicosanoids in structural degradation in osteoarthritis. *Curr Opin Rheumatol.* 15(5):623-7.
  30. Tsai CM, Wu FY, Chai JW, Chen MH, Kao CT. (2020) The advantage of cone-beam computerized tomography over panoramic radiography and temporomandibular joint quadruple radiography in assessing temporomandibular joint osseous degenerative changes. *J Dent Sci.* 15(2):153-62.
  31. Cömert Kiliç S, Kiliç N, Sümbüllü MA. (2015) Temporomandibular joint osteoarthritis: cone beam computed tomography findings, clinical features, and correlations. *Int J Oral Maxillofac Surg.* 44(10):1268-74.
  32. Fu KY, Zhang WL, Liu DG, Chen HM, Ma XC. (2007) [Cone beam computed tomography in the diagnosis of temporomandibular joint osteoarthrosis]. *Zhonghua Kou Qiang Yi Xue Za Zhi.* 42(7):417-20.
  33. Ma RH, Li G, Yin S, Sun Y and Li ZL et al. (2002) XC. Quantitative assessment of condyle positional changes before and after orthognathic surgery based on fused 3D images from cone beam computed tomography. *Clin Oral Investig.* 24(8):2663-72.
  34. Quinn JH, Bazan NG. (1990) Identification of prostaglandin E2 and leukotriene B4 in the synovial fluid of painful, dysfunctional temporomandibular joints. *J Oral Maxillofac Surg.* 48(9):968-71.
  35. Wang XW, Fang W, Li YJ, Long X and Cai HX. (2021) Synovial fluid levels of VEGF and FGF-2 before and

- after intra-articular injection of hyaluronic acid in patients with temporomandibular disorders: a short-term study. *Br J Oral Maxillofac Surg.* 59(1):64-9.
36. Hirota W. (1998) Intra-articular injection of hyaluronic acid reduces total amounts of leukotriene C4, 6-keto-prostaglandin F1alpha, prostaglandin F2alpha and interleukin-1beta in synovial fluid of patients with internal derangement in disorders of the temporomandibular joint. *Br J Oral Maxillofac Surg.* 36(1):35-8.
  37. Li C, Long X, Deng M, Li J, Cai H et al. (2015) Osteoarthritic changes after superior and inferior joint space injection of hyaluronic acid for the treatment of temporomandibular joint osteoarthritis with anterior disc displacement without reduction: a cone-beam computed tomographic evaluation. *J Oral Maxillofac Surg.* 73(2):232-44.
  38. Long X, Chen G, Cheng AH, Cheng Y and Deng M, et al. (2009) A randomized controlled trial of superior and inferior temporomandibular joint space injection with hyaluronic acid in treatment of anterior disc displacement without reduction. *J Oral Maxillofac Surg.* 67(2):357-61.
  39. Li C, Zhang Y, Lv J, Shi Z. (2012) Inferior or double joint spaces injection versus superior joint space injection for temporomandibular disorders: a systematic review and meta-analysis. *J Oral Maxillofac Surg.* 70(1):37-44.
  40. Poveda Roda R, Bagan JV, Díaz Fernández JM, Hernández Bazán S, Jiménez Soriano Y. (2007) Review of temporomandibular joint pathology. Part I: classification, epidemiology and risk factors. *Med Oral Patol Oral Cir Bucal.* 2007;12(4): E292-8.
  41. Kuhn M, Türp JC. (2018) Risk factors for bruxism. *Swiss Dent J.* 128(2):118-24.
  42. Câmara-Souza MB, Carvalho AG, Figueredo OMC, Bracci A, Manfredini D et al. (2020) Awake bruxism frequency and psychosocial factors in college preparatory students. *Cranio.* 1-7.
  43. Osiewicz MA, Lobbezoo F, Bracci A, Ahlberg J, Pytko-Polończyk J et al. (2019) Ecological Momentary Assessment and Intervention Principles for the Study of Awake Bruxism Behaviors, Part 2: Development of a Smartphone Application for a Multicenter Investigation and Chronological Translation for the Polish Version. *Front Neurol.* 10:170.
  44. Zani A, Lobbezoo F, Bracci A, Djukic G and Guarda-Nardini L, et al. (2021) Smartphone-based evaluation of awake bruxism behaviours in a sample of healthy young adults: findings from two University centres. *J Oral Rehabil.* 48(9):989-95.
  45. Bergmann A, Edelhoff D, Schubert O, Erdelt KJ, Pho Duc JM. (2020) Effect of treatment with a full-occlusion biofeedback splint on sleep bruxism and TMD pain: a randomized controlled clinical trial. *Clin Oral Investig.* 24(11):4005-18.
  46. Bussadori SK, Motta LJ, Horliana A, Santos EM, Martimbianco ALC. (2020) The Current Trend in Management of Bruxism and Chronic Pain: An Overview of Systematic Reviews. *J Pain Res.* 13:2413-21.
  47. Mesko ME, Hutton B, Skupien JA, Sarkis-Onofre R, Moher D et al. (2017) Therapies for bruxism: a systematic review and network meta-analysis (protocol). *Syst Rev.* 6(1):4.
  48. White SC, Pharoah MJ. (2008) The evolution and application of dental maxillofacial imaging modalities. *Dent Clin North Am.* 52(4):689-705, v.
  49. Hasselkvist A, Johansson A, Johansson AK. (2016) A 4year prospective longitudinal study of progression of dental erosion associated to lifestyle in 13-14year-old Swedish adolescents. *J Dent.* 47:55-62.
  50. Wänman A, Marklund S. (2020) Treatment outcome of supervised exercise, home exercise and bite splint therapy, respectively, in patients with symptomatic disc displacement with reduction: A randomised clinical trial. *J Oral Rehabil.* 47(2):143-9.
  51. Cai B. (2017) [Physical therapy for temporomandibular joint anterior disc displacement without reduction]. *Zhonghua Kou Qiang Yi Xue Za Zhi.* 52(3):166-70.
  52. Martins WR, Blasczyk JC, Aparecida Furlan de Oliveira M, Lagôa Gonçalves KF, Bonini-Rocha AC et al.

- (2016) Efficacy of musculoskeletal manual approach in the treatment of temporomandibular joint disorder: A systematic review with meta-analysis. *Man Ther.* 21:10-7.
53. Vingender S, Restár L, Csomó KB, Schmidt P and Hermann P et al. (2018) [Intra-articular steroid and hyaluronic acid treatment of internal derangement of the temporomandibular joint]. *Orv Hetil.* 159(36):1475-82.
  54. Isberg A, Widmalm SE, Ivarsson R. (1985) Clinical, radiographic, and electromyographic study of patients with internal derangement of the temporomandibular joint. *Am J Orthod.* 88(6):453-60.
  55. Javanshir K, Amiri M, Mohseni Bandpei MA, De las Penas CF, Rezasoltani A. (2015) The effect of different exercise programs on cervical flexor muscles dimensions in patients with chronic neck pain. *J Back Musculoskelet Rehabil.* 28(4):833-40.
  56. Armijo-Olivo S, Magee D. (2013) Cervical Musculoskeletal Impairments and Temporomandibular Disorders. *Journal of oral & maxillofacial research.* 3: e4.
  57. Armijo-Olivo SL, Fuentes JP, Major PW, Warren S, Thie NM et al. (2010) Is maximal strength of the cervical flexor muscles reduced in patients with temporomandibular disorders? *Arch Phys Med Rehabil.* 91(8):1236-42.
  58. Dutra GA. (2018) Frequência do bruxismo da vigília em universitários. *Odontologia-Pedra Branca.*
  59. Gonçalves SMP. (2019) Avaliação e controle do bruxismo em vigília: relato de caso.
  60. Santos CBPd, Toledo TCPd. (2020) Bruxismo: um desafio no dia a dia do cirurgião dentista.
  61. Clarke P, Craig JV, Wain J, Tremlett C, Linsell L, et al. (2019) Safety and efficacy of 2% chlorhexidine gluconate aqueous versus 2% chlorhexidine gluconate in 70% isopropyl alcohol for skin disinfection prior to percutaneous central venous catheter insertion in preterm neonates: the ARCTIC randomised-controlled feasibility trial protocol. *BMJ Open.* 9(2): e028022.
  62. Privitera GP, Costa AL, Brusaferrero S, Chirletti P, Crosasso P et al. (2017), Massimetti G, et al. Skin antisepsis with chlorhexidine versus iodine for the prevention of surgical site infection: A systematic review and meta- analysis. *Am J Infect Control.* 45(2):180-9.
  63. Sari E, Bakar B. (2018) Which is more effective for pain relief during fractionated carbon dioxide laser treatment: EMLA cream or forced cold air anesthesia. *J Cosmet Laser Ther.* 20(1):34-40.
  64. Litwiniuk M, Krejner A, Speyrer MS, Gauto AR, Grzela T. (2016) Hyaluronic Acid in Inflammation and Tissue Regeneration. *Wounds.* 28(3):78-88.65.
  65. D.F. Ângelo, D. Sanz and H. J. (2003) Cardoso. Effectiveness of double-puncture temporomandibular joint arthrocentesis with viscosupplementation in different categories of severity - a prospective study. *J Craniomaxillofac Surg.* 51(11):659-67.
  66. Sarwar H, Shah I, Khan AA, Afzal M, Babar A et al. (2021). Comparison of arthrocentesis plus platelet rich plasma with arthrocentesis alone in the treatment of temporomandibular joint dysfunction. *Paki Armed Forces Med J.* 71(4):1377-81.
  67. Januzzi E, Cunha TCA, Silva G, Souza BDM, Duarte ASB et al. (2022). Viscosupplementation in the upper and lower compartments of the temporomandibular joint checked by ultrasonography in an ex vivo and in vivo study. *Scientific reports.* 12(1):17976.