

Journal of Clinical Practice and Medical Case Report

Genesis-JCPMCR-1(2)-12
Volume 1 | Issue 2
Open Access
ISSN: 3048-8206

Pattern of Third Molar Impaction Among Males and Females of Vikarabad

V. Nagalaxmi¹, Ayesha Sadathullah^{1*}, Rishika Reddy¹, Sunayana Abbagalla¹ and Enaganti Srishitha¹

¹Sri Sai College of Dental Surgery

*Corresponding author: Ayesha Sadathullah, Sri Sai College of Dental Surgery, Hyderabad, India.

Citation: Nagalaxmi V, Sadathullah A, Reddy R, Abbagalla S, Srishitha E. Pattern Of Third Molar Impaction Among Males and Females of Vikarabad . J Clin Pract Med Case Rep. 1(2):1-11.

Received: September 28, 2024 | **Published:** October 10, 2024

Copyright © 2024 genesis pub by Nagalaxmi V. CC BY-NC-ND 4.0 DEED. This is an open-access article distributed under the terms of the Creative Commons Attribution-Non Commercial-No Derivatives 4.0 International License. This allows others distribute, remix, tweak, and build upon the work, even commercially, as long as they credit the authors for the original creation

Abstract

This study presents a comprehensive evaluation of the pattern and angulations of third molar impactions in a sample of 514 individuals (comprising both males and females) from Vikarabad utilizing orthopantomogram (OPG) imaging. The primary objective is to identify types of patterns and degree of angulations in third molar impactions between genders in this specific population. Third molar impaction, a prevalent dental condition that poses challenges in dental management and varies significantly across different populations and genders. Orthopantomograms from 514 patients were retrospectively analyzed based on the presence of at least one third molar impaction. The sample was stratified among males and females with ages ranging from 18 to 60 years. Results indicated horizontal impactions were most common (33.7%), followed by mesioangular (24.5%) and buccolingual (17.1%). Vertical and distoangular impactions accounted for 13.2% and 11.1% respectively, while inverted impactions were rare (0.4%).

Keywords

Third molar impaction; Orthopantomogram; Angulation

Introduction

Impaction or impacted tooth is defined as a “tooth which is completely or partially unerupted and is positioned against another tooth, bone or soft tissue so that its further eruption is unlikely, described according to its anatomic position” [1]. Third molar is the most common impacted tooth in the oral cavity [2]. The prevalence of the third molar impaction ranges from 16.7% to 68.6%.³⁻⁶ Generally, third molars erupt between the ages of 17 and 21 years [3]. The epidemiology of third molar impactions is multifaceted, influenced by a range of biological, environmental, and social factors,⁵ such as nature of the diet that may lead to attrition, reduced mesiodistal crown diameter, degree of use of the masticatory forces and genetic inheritance may also affect the timing of third molar eruption [6]. Other local factors such as prolonged deciduous tooth retention, malposed tooth germs, arch-length deficiency, supernumerary teeth, odontogenic tumors abnormal eruption path, and cleft lip and palate [4-6].

Various theories have been hypothesized in the literature for the impaction of the third molar [7]. It has been suggested with gradual evolution there has been reduction in the size of the human mandible/maxilla which resulted in comparatively small mandible/maxilla which has become resistant to accommodate the corresponding molars.⁸ It has also been proposed that the modern diet does not offer high forces during mastication, which results in loss of growth stimulation of jaws, and thus the modern man has more number of impacted and unerupted teeth [9].

The clinical significance of third molar impaction lies in its potential to cause a range of dental complications and challenges [10]. Impacted third molars can lead to pericoronitis, form cysts, and even tumors in many cases [11]. They pose a risk of damaging adjacent teeth, either through direct pressure or increased susceptibility to dental caries and periodontal disease due to difficulty in maintaining proper hygiene [12]. The necessity for surgical removal, which carries its own risks and considerations, further underscores their clinical importance [13]. Additionally, these impactions can complicate orthodontic treatments by causing crowding or displacement of teeth [14].

Various methods have been used to classify impaction, in which impaction is described based on the level of impaction,¹⁵ the angulations of the third molars,¹⁵ and the relationship to the anterior border of the ramus of the mandible [16].

Depth or level of maxillary and mandibular third molars can be classified using the Pell and Gregory classification system,¹⁵ where the impacted teeth are assessed according to their relationship to the occlusal surface of the adjacent second molar. If the third molar is at the same level or above the occlusal surface of the adjacent second molar, then it is classified as “A”. If it is between the occlusal surface and the cervical line of the second molar, then it is classified as “B”. Level “C” is when the third molar is below the cervical line of the adjacent second molar [15] (Table:1 and Figure 1).

Level	Definition
Level A	Not buried in Bone
Level B	Partially buried In Bone
Level C	Completely buried in Bone

Table 1: Pell and Gregory's classification of third molar impaction by level of the impaction.

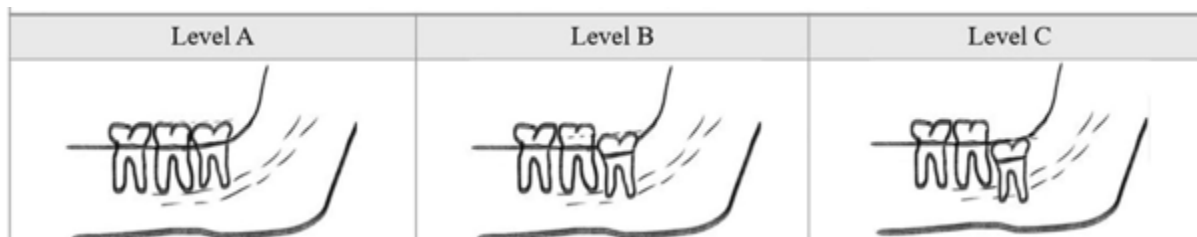


Figure 1: Pell and Gregory's classification [15].

Another classification of third molar impaction is according to their angular relationship to the adjacent second molar. Angulation of the impacted third molar was determined by evaluating the angle formed between the intersected longitudinal axis of the impacted third molar with that of the adjacent second molar, as described by Winter,¹⁶ either visually or by using an orthodontic protractor.

Level of Impaction	Angulation of third molar to second molar
Vertical Impaction	10° to - 10°
Mesioangular Impaction	11° to 79°
Horizontal Impaction	80° to 100°
Distoangular Impaction	-11° to - 79°
Buccolingual Impaction	-

Table 2: Winter's classification of third molar impaction.

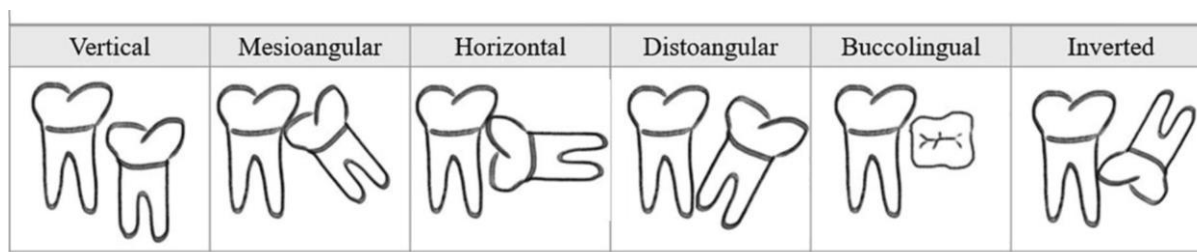


Figure 2: Winter's classification.

molar impaction and the degree of angulation among males and females of Vikharabad. Orthopantomography (OPG), is an invaluable tool in dentistry for evaluating third molar impactions. It provides a comprehensive view of the entire dental arch, enabling accurate assessment of the site, location, and angulation of impacted third molars, which is essential for effective treatment planning and surgical intervention.¹⁸ This imaging technique is particularly useful for visualizing the relationship of impacted teeth to adjacent anatomical structures, such as the inferior alveolar nerve and the maxillary sinus [18]. The aim of the present study is to analyze the pattern of third

Materials and Methods

In the present study the records of 1273 patients visiting Sri Sai college of Dental Surgery between the year 2023-2024 were reviewed using Carestream dental machine (serial number:BIAM545) in dental imaging software (kVp-73, mA-12 and time-13.9 seconds). 514 OPGs were selected of males and females between the age of 18-60 years and their related data was selected from this record. Remaining 62% were excluded for one of the following reasons: aged younger than 18 years or above 60 years; history of previous dental extraction; orthodontic treatment or dento-alveolar trauma; incomplete root formation of the third molars; any pathological dento-alveolar condition and due to incomplete records or poor quality OPG.

Method

OPGs were reviewed to determine the prevalence of impacted third molars their levels of eruption and their angulations. Third molar was considered as impacted if it was not in functional occlusion but with fully developed roots with closed apex. The level of impaction was determined according to the relationship of the third molar relative to the occlusal level of adjacent second molar and the angulation was assessed by measuring the angle formed between the long axis of the third molar relative to the long axis of the adjacent second molar, using a protractor and the collected data was reviewed by a statistician.

Results

Statistical analysis: The data collected was entered in the Microsoft Excel sheet by the examiner and analyzed using the Statistical Package for Social Sciences (SPSS) package version 22 (IBM Corp. in Armonk, New York, USA). The normality of the data was tested using the Shapiro-Wilk test. Demographic details and impaction-related characteristics were presented in the form of percentages. A comparison of the level of impaction based on gender was done using the Chi-Square test. $p \leq 0.05$ is considered to be statistically significant.

Demographic Distribution: The study on the pattern of third molar impaction among males and females in Vikharabad provides comprehensive insights into the demographic characteristics and impaction levels observed in a sample size of 514 individuals, comprising 267 males (51.9%) and 247 females (48.1%) (Table 3).

Gender	n	%
Males	267	51.9
Females	247	48.1
Total sample	514	100

Table 3: Demographic details – gender.

Age Distribution

The mean age for males was found to be 29.99 years with a standard deviation (SD) of 9.47, while for females, the mean age was slightly lower at 28.14 years with an SD of 7.64 (Table 4) This indicates a relatively young population affected by third molar impaction, with a slight variation in age distribution between genders.

	Mean age	SD
Males	29.9888	9.46957
Females	28.1377	7.63851

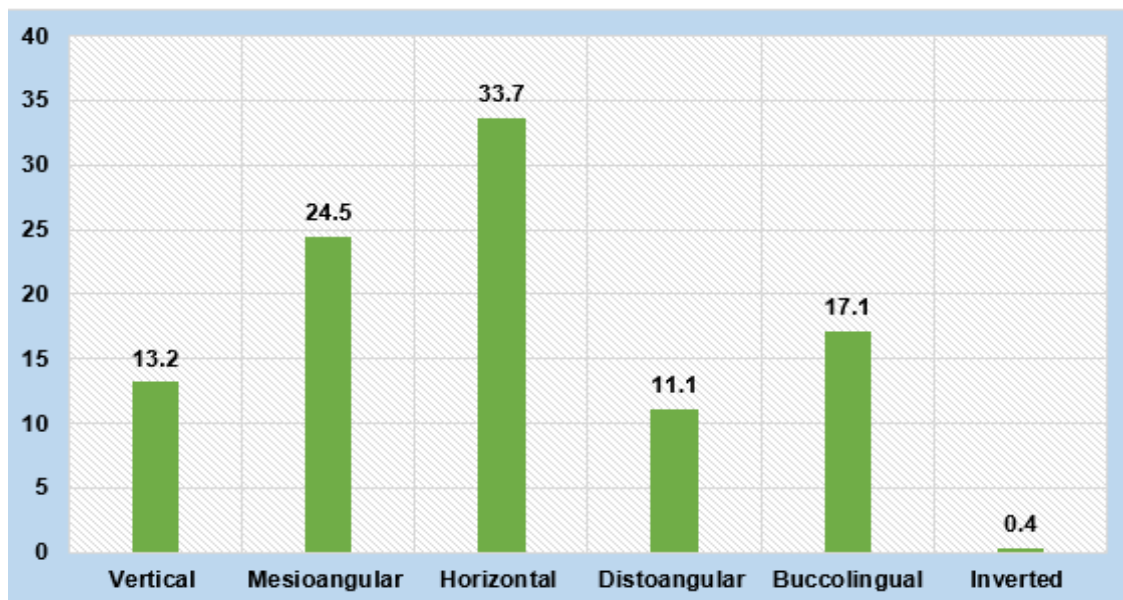
Table 4: Descriptive of age.

Levels of Impaction

The study classified the levels of impaction into six categories: vertical, mesioangular, horizontal, distoangular, buccolingual, and inverted. The most common type of impaction was horizontal, observed in 33.7% of the cases, followed by mesioangular at 24.5%, and buccolingual at 17.1%. Vertical and distoangular impactions were less common, accounting for 13.2% and 11.1% respectively, while inverted impactions were rare at only 0.4% (Table 5 and Graph 1).

Level of impaction	n	%
Vertical	68	13.2
Mesioangular	126	24.5
Horizontal	173	33.7
Distoangular	57	11.1
Buccolingual	88	17.1
Inverted	2	0.4

Table 5: Distribution based on level of impaction.



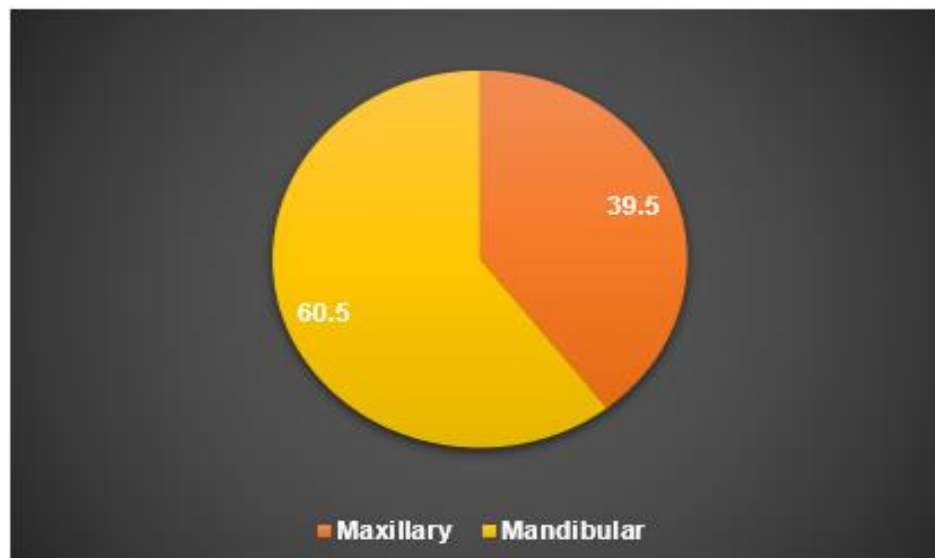
Graph 1: Distribution based on level of impactation.

Impactation Based on Arch

When analyzing the distribution of impactations based on the dental arch, a higher prevalence was noted in the mandibular arch (60.5%) compared to the maxillary arch (39.5%). This suggests a tendency for third molar impactations to occur more frequently in the lower jaw (Table 6 and Graph 2).

Arch	n	%
Maxillary	203	39.5
Mandibular	311	60.5

Table 6: Distribution of impactation based on the arch.



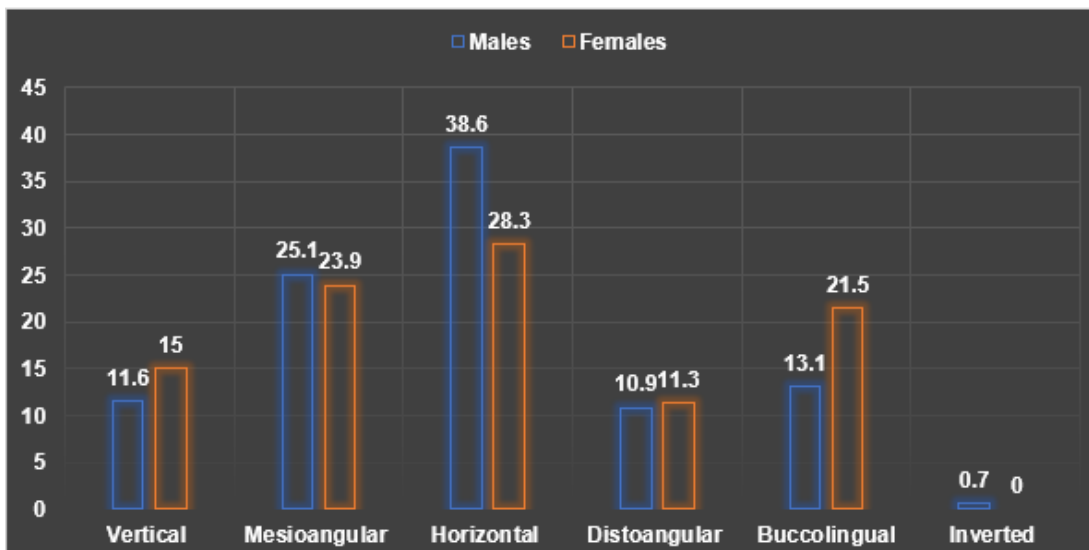
Graph 2: Distribution of impaction based on the arch.

Gender-Based Comparison

A significant finding from the study is the gender-based comparison of impaction levels. Horizontal impactions were more prevalent among males (38.6%) compared to females (28.3%). Conversely, buccolingual impactions were more common in females (21.5%) than in males (13.1%). Mesioangular, vertical, and distoangular impactions showed relatively similar distributions between genders, with mesioangular impactions at 25.1% in males and 23.9% in females, vertical at 11.6% in males and 15% in females, and distoangular at 10.9% in males and 11.3% in females. Inverted impactions were observed only in males (0.7%) and not in females. (Table 7 & Graph 3). The chi-square test indicated that these differences were statistically significant for vertical and buccolingual impactions ($p < 0.05$).

Level of impaction	Males		Females		P value
	N	%	n	%	
Vertical	31	11.6	37	15	0.031*
Mesioangular	67	25.1	59	23.9	
Horizontal	103	38.6	70	28.3	
Distoangular	29	10.9	28	11.3	
Buccolingual	35	13.1	53	21.5	
Inverted	2	0.7	0	0	

Table 7: Comparison of the level of impaction based on gender.



Graph 3: Comparison of the level of impaction based on gender.

These findings provide valuable data for dental practitioners in Vikharabad, highlighting the need for gender-specific approaches in the diagnosis and management of third molar impactions. The higher prevalence of certain impaction types in specific genders suggests that tailored treatment plans could improve patient outcomes and reduce the complications associated with third molar extractions.

Discussion

The study on the pattern of third molar impaction among males and females in Vikharabad offers a detailed analysis of the epidemiological characteristics and clinical implications of this common dental issue. Utilizing orthopantomograms (OPG) for accurate assessment, the research provides valuable insights into the prevalence, types, and angulation of third molar impactions, along with a gender-based comparison.

The demographic distribution in the study ensures a balanced representation of both genders, allowing for a comprehensive analysis of third molar impactions in males and females. This balance is crucial for understanding how third molar impactions affect different genders and for developing gender-specific treatment approaches. The mean age of participants, with males averaging [29]. 99 years and females 28.14 years, highlights the young adult population as the primary demographic affected by third molar impactions. This age range is significant for dental practitioners as it encompasses the period when preventive and corrective measures can be most effective.

The study categorized third molar impactions into six types: vertical, mesioangular, horizontal, distoangular, buccolingual, and inverted.¹⁶ This classification is essential for understanding the complexity and potential complications associated with each type.¹⁶ Horizontal impactions were the most common, followed by mesioangular and buccolingual impactions. These findings are consistent with previous studies, indicating that horizontal and mesioangular impactions pose significant challenges due to their alignment and potential impact on adjacent teeth. Buccolingual and vertical impactions, while less common, still represent a considerable portion of cases and require specific clinical attention.

The higher prevalence of impactions in the mandibular arch (60.5%) compared to the maxillary arch (39.5%) is a critical finding. This pattern is aligned with the anatomical and developmental differences between the maxilla and mandible. The mandible is dense bony structure that has limited space for eruption which makes it more prone to impactions [6]. This knowledge is essential for dentists, as it emphasizes the importance for vigilant monitoring and proactive management of impacted mandibular third molars [11]. Understanding this distribution can help the clinicians in prioritizing diagnostic and therapeutic efforts towards the mandibular arch, potentially reducing complications and improving outcome for the patients [11].

The gender-based analysis revealed significant differences in the patterns of third molar impactions. Males exhibited a higher prevalence of horizontal impactions, which could be attributed to differences in jaw size and growth patterns. In contrast, females had a higher incidence of buccolingual impactions, suggesting variations in dental arch dimensions and tooth size between genders. The statistically significant differences in vertical and buccolingual impactions underscore the importance of considering gender-specific anatomical and developmental factors when planning treatment. This gender-specific approach can enhance the effectiveness of interventions and reduce the risk of complications.

The findings from this study have several critical implications for dental practice. The high prevalence of certain types of impactions, particularly horizontal and mesioangular, highlights the need for early diagnosis and intervention. Regular monitoring and proactive management strategies can prevent complications such as pericoronitis, cyst formation, and damage to adjacent teeth.⁷ The use of orthopantomograms (OPG) proved invaluable in accurately assessing the site, location, and angulation of impacted third molars [8]. This imaging technique should be an integral part of routine dental examinations for young adults, enabling precise diagnosis and effective treatment planning [10].

This study, while comprehensive in its scope, has several limitations that must be acknowledged. Firstly, the reliance on radiographic data, specifically orthopantomogram (OPG), may not capture the complete clinical picture of third molar impactions, as radiographs can sometimes fail to show the full extent of soft tissue involvement and other anatomical nuances. Secondly, the retrospective nature of the study means that it is dependent on the accuracy and completeness of existing records, which could introduce biases or inconsistencies in the data. Additionally, the study's sample was drawn from a single geographic region, Vikharabad, which may limit the generalizability of the findings to other populations with different genetic, dietary, and environmental factors influencing third molar development and impaction patterns.

Future research should aim to address these limitations by incorporating a prospective study design and including multiple geographic locations to enhance the generalizability of the findings. Longitudinal studies would be particularly valuable in understanding the dynamic process of third molar impaction over time and the long-term outcomes of different management strategies. Furthermore, integrating advanced imaging techniques, such as cone-beam computed tomography (CBCT), could provide more detailed insights into the spatial relationships and morphological characteristics of impacted third molars. Investigating the genetic and environmental factors that contribute to third molar impaction, as well as exploring the efficacy of preventive measures, could also provide valuable information for improving clinical practices and patient outcomes.

Conclusion

The study on the pattern of third molar impaction among males and females in Vikharabad provides valuable insights into the epidemiological characteristics and clinical implications of this common dental condition. The findings highlight the significant prevalence of various impaction types, with horizontal and mesioangular impactions being the most common. The gender-based analysis revealed distinct patterns, emphasizing the need for gender-specific approaches in the diagnosis and management of third molar impactions. The study underscores the importance of using orthopantomograms (OPG) for accurate assessment, which is crucial for effective treatment planning and management. Despite the limitations, including the reliance on radiographic data and the study's regional focus, the research contributes to the growing body of knowledge on third molar impactions. It provides a foundation for future research and can aid dental practitioners in making more informed decisions regarding the management of these cases. Further studies, incorporating advanced imaging techniques and broader geographic samples, are needed to enhance our understanding of the factors influencing third molar impactions and to improve patient care and outcomes.

References

1. Janakiraman EN, Alexander M, Sanjay P. (2010) Prospective analysis of frequency and contributing factors of nerve injuries following third-molar surgery. *J Craniofac Surg.* 21:784-6.
2. Dachi SF, Howell FV. (1961) A survey of 3,874 routine full-mouth radiographs. II. A study of impacted teeth. *Oral Surg.* 14:1165-69.
3. Hattab FN, Fahmy MS, Rawashedeh MA. (1995) Impaction status of third molars in Jordanian students. *Oral Surg Oral Med Oral Pathol Radiol Endod.* 79(1):24-29.
4. Scherstén E, Lysell L, Rohlin M. (1989) Prevalence of impacted third molars in dental students. *Swed Dent J.* 13(1-2):7-13.
5. Pedersen GW. (1988) Surgical removal of teeth. In: Pedersen GW, editor. *Oral Surgery.* Philadelphia, PA: WB Saunders. 2(1):47-81.
6. Brown LH, Berkman S, Cohen D, Kaplan AI, Rosenberg M. (1982) A radiological study of the frequency and distribution of impacted teeth. *J Dent Assoc S Afr.* 37(9):627-30.
7. Bouloux GF, Steed MB, Perciaccante VJ. (2007) Complications of third molar surgery. *Oral Maxillofac Surg Clin North Am.* 19:117-28, vii.
8. Juodzbaly G, Daugela P. (2013) Mandibular third molar impaction: Review of literature and a proposal of a classification. *J Oral Maxillofac Res.* 4(2): e1.
9. Grover PS, Lorton L. (1985) The incidence of unerupted permanent teeth and related clinical cases. *Oral Surg Oral Med Oral Pathol.* 59:420-5.
10. Ajith SD, Shetty S, Hussain H, Nagaraj T, Srinath M. (2014) Management of multiple impacted teeth: A case report and review. *J Int Oral Health.* 6:93-8.
11. Akadiri OA, Obiechina AE. (2009) Assessment of difficulty in third molar surgery—a systematic review. *Journal of Oral and Maxillofacial Surgery.* 67(4):771-4.
12. Marciani RD. (2007) Third molar removal: an overview of indications, imaging, evaluation, and assessment of risk. *Oral and Maxillofacial Surgery Clinics.* 19(1):1-3.
13. Meechan JG, Seymour RA. (1993) The use of third molar surgery in clinical pharmacology. *British journal of oral and maxillofacial surgery.* 31(6):360-5.
14. Cheng HC, Peng BY, Hsieh HY, Tam KW. (2018) Impact of third molars on mandibular relapse in post-orthodontic patients: A meta-analysis. *Journal of dental sciences.* 13(1):1-7.

15. Brown LH, Berkman S, Cohen D, Kaplan AI, Rosenberg M. (1982) A radiological study of the frequency and distribution of impacted teeth. *J Dent Assoc S Afr.*37(9):627-30.
16. Fanning EA, Moorees CF. (1969) A comparison of permanent mandibular molar formation in Australian aborigines and Caucasoids. *Arch Oral Biol.*14(9):999–1006.
17. Chomenko AG. (1985) *Atlas for maxillofacial pantomographic interpretation*, Chicago, 1985, Quintessence
18. White SC, Pharoah MJ, (2014) *Oral Radiology Principles and Interpretation*, 7th Edition, Elsevier, Health Sciences Division, Amsterdam. 41-63.
19. Haidar Z, Shalhoub SY. (1986) The incidence of impacted wisdom teeth in a Saudi community. *Int J Oral Maxillofac Surg.* 15(5):569–71.