

Advances in Clinical and Medical Research

Genesis-ACMR-4(1)-47
Volume 4 | Issue 1
Open Access
ISSN: 2583-2778

Forgotten Right Ventricle Entity: in Post Acute Covid Symptomatic (PASC) Patients

Atul Kapoor* and Goldaa Mahajan**

Department of Radiology, Advanced Diagnostics and Institute of Imaging. Amritsar, India

***Corresponding author:** Atul Kapoor, Department of Radiology, Advanced Diagnostics and Institute of Imaging. Amritsar, India

Citation: Kapoor A, Mahajan G. (2022) Forgotten Right Ventricle Entity: in Post Acute Covid Symptomatic (PASC) Patients. *Adv Clin Med Res.* 4(1):1-3.

Received: January 9, 2023 | **Published:** January 30, 2023

Copyright© 2023 genesis pub by kapoor A, et al. CC BY-NC-ND 4.0 DEED. This is an open-access article distributed under the terms of the Creative Commons Attribution-NonCommercial-No Derivatives 4.0 International License. This allows others distribute, remix, tweak, and build upon the work, even commercially, as long as they credit the authors for the original creation.

Introduction

World has just passed through the global pandemic of Covid-19 disease with recent reports of it resurfacing in China. Although being a disease predominantly affecting lungs the involvement of other organs like heart, brain and gut have also been seen in the acute phase. PASC (post acute SARS Covid-19) is another distinct phase of the disease seen amongst survivors from both mild and severe disease where the patients continue to suffer from symptoms of palpitations, dysnoea on exertion, chest pain and fatigue. Few studies have been done in such patients to assess ongoing cardiac involvement. Most of these patients show normal left and right ventricle Ejection fraction, normal troponin levels with nonspecific EKG findings of sinus tachycardia. Some of these patients are made to undergo cardiac MR to rule out covid-19 myocarditis. Here also most of the imaging specialists and the cardiologists are focused on the left ventricle only and look for the Lake Loius criteria to establish or rule out diagnosis.

In a study by Lan, et al [1] it was shown that the right ventricle was commonly involved in Covid-19 disease and the reasons attributable were due to proximity of right ventricle with pulmonary circulation, increased after load of right ventricle due to Covid-19 lung complications, increased surface area of right ventricle free wall and direct involvement of right ventricle wall by the virus. Similarly studies by Li et al [2]

Short-Commentary | Kapoor A, et al. *Adv Clin Med Res* 2023, 4(1)-47.

DOI: [https://doi.org/10.52793/ACMR.2023.4\(1\)-47](https://doi.org/10.52793/ACMR.2023.4(1)-47)

and Lee et al [3] also showed the prognostic value of myocardial strain in Covid-19 disease and altered right ventricular strain in acute Covid-19 carried a poor prognosis. In the PASC phase the etiology of myocarditis remains elusive as is the challenge of establishing the diagnosis. Studies done by Puntmann, et al [4], Huang et al [5] have shown the use of CMR with multiparametric mapping to diagnosis myocarditis in PASC patients. Yet in all these studies the findings for a positive diagnosis were elicited by showing changes in the left ventricle myocardium only with most of the patients showing normal Left and right ventricle size and function. Hence this entity of “forgotten right ventricle in PASC”. In a follow up study done in athletes who recovered from Covid -19 disease Wassener et al [6] showed strain abnormalities of left ventricle only and were silent about the changes in right ventricle even though prior studies demonstrated the common involvement of right ventricle. Only a recent study done by the author Kapoor, et al [7] using multiparametric CMR along with feature tracking for both left and right ventricles showed that there was equal and severe involvement of right ventricle wall with diffuse increased signal changes on T2 maps even on the follow up of recovered Covid-19 patients (Figure 1). Their study showed 16% and 9% reduction of systolic global circumferential shortening and 61% and 48% reduction early diastolic strain rate of the left and right ventricle respectively. They showed that the use of the above technique was valuable in not only diagnosing the condition but also staging the extent of disease which could impact the management of these patients. So in PASC patients its pertinent to have a detailed right ventricle evaluation and not to be taken by the forgotten right ventricle entity. Unfortunately not much emphasis is being given to the detailed right ventricle assessment apart from its size and wall motion abnormalities.

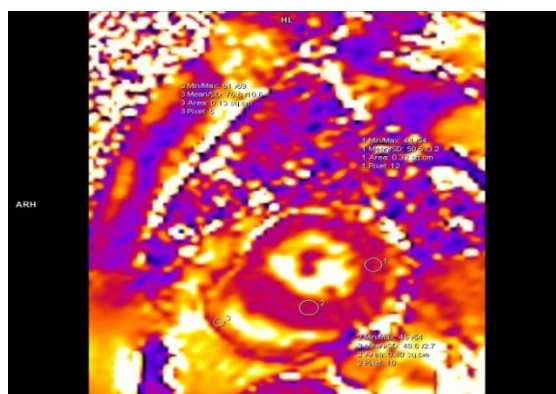


Figure 1: T2 parametric map mid-ventricle short axis view on Cardiac MRI showing focal increased signal intensity changes in left ventricle walls and diffuse edema in the free right ventricle wall.

Conclusion

In conclusion the forgotten right ventricle entity in PASC not only eludes the patient of a diagnosis of ongoing myocarditis but also can have a long term bearing on the prognosis as these patients may finally end up in cardiomyopathy of the right ventricle. It would be therefore prudent to evaluate these patients using multi parametric cardiac MR techniques with myocardial strain evaluation rather than stopping at routine echocardiograms alone. All patients who have severe impairments need to be followed up for any progression of disease.

References

1. Lan Y, Liu W, Zhou Y. (2021) Right ventricle Damage in Covid-19: Association between Myocardial Injury and Covid-19. *Front cardiovasc Med.* 8:606318.
2. Li Y, Li H, Zhu S, Xie Y, Wang B, et al. (2020) Prognostic value of right ventricular longitudinal strain in patients with COVID-19. *JACC. Cardiovasc Imaging.* 13:2287–99.
3. Lee JW, Jeong YJ, Lee G, et al. Predictive Value of Cardiac Magnetic Resonance Imaging-Derived Myocardial Strain for Poor Outcomes in Patients with Acute Myocarditis. *Korean J Radiol.* 18(4):643–65.
4. Puntmann VO, Martin S, Shchendrygina A, Hoffmann J, MM Ka , et al. (2022) Long-term cardiac pathology in individuals with mild initial COVID-19 illness. *Nature Medicine.* 28(10):2117–23.
5. Huang L, Zhao P, Tang D, Zhu T, Han R, et al. (2020) Cardiac involvement in patients recovered from COVID-2019 identified using magnetic resonance imaging. *JACC Cardiovasc Imaging.* 13(11):23330-39.
6. Wassenaar JW, Clark DE, Dixon D, Durrett KG, Parikh A, et al. (2022) Reduced Circumferential Strain in Athletes with Prior COVID-19 Infection. *Radiol Cardiothorac Imaging* 4(4):e210310
7. Kapoor A, Kapur A. (2022) Myocardial strain abnormalities in patients with long Covid after mild to moderate Covid-19 disease. *J cardiol cardiovas Res.* 6(4): 109-17.